

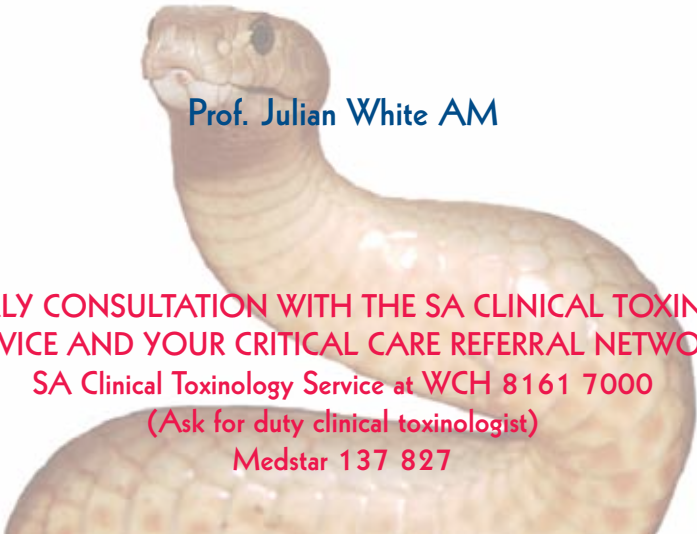

Government of South Australia
Department of Health

SNAKEBITE & SPIDERBITE

Management Guidelines South Australia

Prof. Julian White AM



**SEEK EARLY CONSULTATION WITH THE SA CLINICAL TOXINOLOGY
SERVICE AND YOUR CRITICAL CARE REFERRAL NETWORK**

SA Clinical Toxinology Service at WCH 8161 7000

(Ask for duty clinical toxicologist)

Medstar 137 827

ACKNOWLEDGEMENTS

Firstly I wish to acknowledge my colleagues in the Toxinology Dept., Women's & Children's Hospital, Assoc. Prof. Scott Weinstein and Dr. Sam Alfred (Sam is an honorary at WCH; he is a full time emergency physician and toxicologist at nRAH ED). Scott and Sam have not only been through this document, making suggestions, but help provide the clinical toxinology services referred to in the document, particularly Scott, with whom I share the majority of on-call work.

I would also like to thank the many colleagues, both in SA and beyond, whose comments on the drafts and earlier versions of this document have helped improve it and also those colleagues who have shared cases of envenoming with me over the last forty plus years. That shared experience, combined with the many cases I have managed personally, has formed the background knowledge on which this document is based. The support of colleagues here in SA has, and will remain, crucial in realising projects such as this. These revised SA guidelines are based on the 2006 guidelines. However, I have added some special extras for the SA version. I am particularly grateful to the following colleagues in SA whose help enabled me to undertake producing the original 2006 edition; Dr. Chris Baggoley, Sue Glen, Dr. Jeremy Raftos, Alan Staples, Dr. Mark Hutchinson (who also supplied some photos), Dr. Bill Giriggs.

A number of naturalist, herpetologist and arachnologist colleagues also assisted in the first version, by providing personal perspectives on distribution and abundance of venomous animals. Harrold Ehmman and Mike Gray were especially important in this process.

Lastly I would like to thank those in Adelaide whose forbearance about the time spent producing this document was crucial; my colleagues in the Division of Paediatric Medicine, Women's and Children's Hospital and my family, who have missed me most during this process.

Julian White
February 2018

Published by the Department of Health, Adelaide 2018

Copyright © Women's & Children's Hospital & Department of Health (SA)

Prof. Julian White asserts his moral right to be recognised as the author of this publication.

**National Library of Australia Cataloguing-in-Publication:
White, Julian.**

**Snakebite & spiderbite : management guidelines South
Australia.**

ISBN 0 7308 9551 3.

1. Poisonous snakes - Venom - Toxicology - South Australia.

2. Poisonous spiders - Venom - Toxicology - South

Australia. 3. Bites and stings - South Australia. 4.

Snakebites - South Australia. I. South Australia.

Department of Health. II. Title.

615.942099423

**This document may be copied within Australia by medical
and paramedical staff for the purposes of patient care and
medical education.**

DEPARTMENT OF HEALTH, GOVERNMENT OF SOUTH AUSTRALIA

March 2018

Except where noted, all algorithms and illustrations, including photos are copyright © Prof. Julian White

HOW TO USE THIS BOOK

EMERGENCY INFORMATION

This section is designed to provide brief information for rapid assimilation and use.

Brief information on the following topics may be found on the following pages:

Snakebite overview:	Page	5
Snakebite clinical pathway:	Page	9
Snakebite flow chart:	Page	10
Methods for determining type of snake if no venom detection result:	Page	12
Major patterns of clinical and laboratory findings after snakebite:	Page	13
Country hospital decision algorithm:	Page	14
Redback Spiderbite overview:	Page	18
Redback spider flowchart:	Page	19
Funnel web spiderbite overview:	Page	20
Funnel web spider flowchart:	Page	21
Marine stings/poisonings overview:	Page	22
List of venomous animals for each hospital hinterland:	Page	78
List of recommended antivenom stocks for each hospital:	Page	79

**SEEK EARLY CONSULTATION WITH THE
SA CLINICAL TOXINOLOGY SERVICE
Clinical Toxinology Service SA (WCH)**

**Ring WCH8161 7000 and ask for duty Clinical Toxinologist
WCH 8161 7000
Medstar 137 827**

DETAILED INFORMATION

This section is designed to provide more comprehensive information, including management guidelines and details on animals of particular importance.

A detailed listing is provided in the Contents page (next page). An overview of major topics is listed below:

Snakes and snakebite:	Page	23
Management guidelines:	Page	23
Details of snakes:	Page	39
Spiders and spiderbite:	Page	63
Redback spiders:	Page	63
Funnel web spiders:	Page	66
Other arthropods:	Page	71
Marine envenoming & poisoning:	Page	22
Reading List:	Page	76

TABLE OF CONTENTS

SECTION 1 - EMERGENCY INFORMATION	3
SECTION 2 - SNAKEBITE (detailed information)	23
Protocol for Managing a Case of Snakebite in a hospital with antivenom available	23
Treatment of the envenomed or possibly envenomed patient	23
Criteria for systemic envenoming	24
Snake venom detection kit	25
Antivenom therapy	28
Antivenom dose	28
Management of anaphylaxis	29
Management of the patient who initially appears well	30
Management of the severely ill patient where the diagnosis is obscure	31
Snakebite coagulopathy - defibrination	32
Snakebite coagulopathy - anticoagulation	34
Snakebite myolysis	34
Snakebite neurotoxic paralysis	35
Follow up of snakebite patients	35
Protocol for Managing a Case of Snakebite in a Hospital Without Antivenom Available	36
Identifying snakes	37
Details of Major Venomous Snakes	39
Scalation Comparison Table	40
Brown Snakes	42
Tiger Snakes	45
Rough-scaled Snake	46
Copperheads	47
Broad-headed snakes (includes Stephen's Banded Snake & Pale-headed Snake)	48
Mulga Snake or King Brown	50
Red-bellied Black Snake	51
Blue-bellied or Spotted Black Snake	52
Collett's snake	53
Death Adders	54
Taipans	55
Eastern Small-eyed Snake	57
Yellow-faced Whip Snake	57
Other Elapid Snakes	58
SECTION 3 - SPIDERBITE & OTHER ARTHROPODS	63
Red Back Spider	63
Funnel Web Spiders	66
Protocol for managing funnel web spiderbite	60
Miscellaneous Spiders and Other Arthropods	71
Scorpions	74
SECTION 4 - RECOMMENDED READING	76
SECTION 5 - RECOMMENDED ANTIVENOM STOCKS	77

AN OVERVIEW OF SNAKEBITE MANAGEMENT

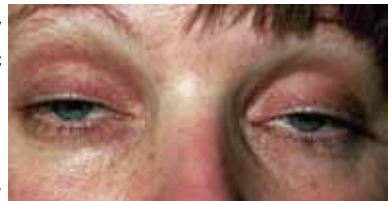Snakebite is a potential medical emergency and should always receive high priority assessment and treatment, even if the patient appears initially well. The **majority of snakebites** will not result in significant envenoming and **will not require antivenom**.

- **Beware** the patient with a history of **multiple bites**; in most such cases major envenoming will occur, requiring increased amounts of antivenom.
- **Admit all cases** of probable snakebite at least for 12 hours after the bite or after removal of effective first aid, or overnight, preferably to a high dependency ward; insert IV line, give IV fluids. No patient with suspected snakebite should be discharged in the evening or during the night or to a situation where no other adult is able to observe them over the following 24hrs.
- **Manage cases only in hospitals fully equipped to do so**, including laboratory facilities on-site, adequate stocks of appropriate antivenom.

Major problems may include one or more of the following effects of the venom (note these are principally systemic rather than local effects):

- **Paralysis**; block transmission at the neuromuscular junction causing skeletal and respiratory muscle flaccid paralysis, either presynaptic and/or postsynaptic.

SIGNS: ptosis (drooping of upper eyelids), diplopia (double vision), ophthalmoplegia (partial or complete paralysis of eye movements), fixed dilated pupils, muscle weakness, respiratory problems.



Ptosis following tiger snake bite.

- **Coagulopathy**; cause *either* (1) defibrination with low fibrinogen, unclottable blood but usually normal platelet count, *or* (2) direct anticoagulation, with normal fibrinogen and platelet count. Both types may cause elevated prothrombin ratio (INR) or prolonged aPTT.

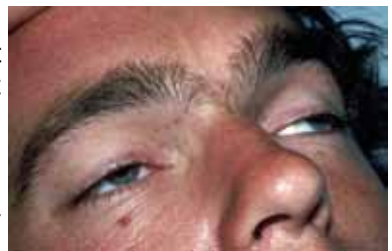SIGNS: bleeding from bite, gums, venepunctures, rarely haematemesis, haematuria etc.

- **Myolysis**; cause generalised destruction of skeletal muscle with high serum CK (creatinine kinase) and myoglobinuria (red to brown urine testing positive for blood; can be confused with true haematuria), occasionally secondary AKI and severe hyperkalaemia.

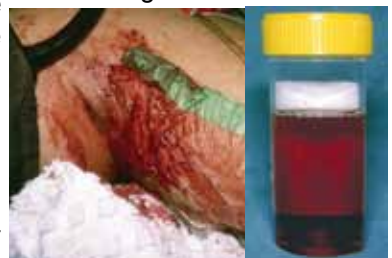SIGNS: muscle movement pain or weakness, red or brown urine.

- **Renal Damage**: primary or secondary (myolysis, coagulopathy) acute kidney injury.

SIGNS: oliguria (decreased urine output), anuria (no urine output) etc.



Ptosis and partial gaze paralysis following death adder bite



Oozing from venepuncture site and dark red urine of myoglobinuria.

General symptoms include; headache, nausea, vomiting, abdominal pain, collapse, convulsions. Beware anxiety as a cause of general symptoms.

Local symptoms vary from minimal to obvious bite marks, local pain, swelling, or bruising. **A trivial looking bite site does not mean a trivial bite.** Punctures or scratches may occur.

FIRST AID - Pressure Immobilisation Bandage & Splint (PBI):

Maintain airway/breathing if impaired. Immediately apply a broad compressive bandage to the bite site at same pressure as for a sprain. Extend the bandage to cover the whole of the bitten limb including fingers/toes. Splint limb. Keep patient still; bring transport to patient. **DO NOT** give alcohol, food, stimulants, or cut the wound, or use a tourniquet. **DO NOT WASH OR CLEAN THE WOUND.** Leave PIB in place until patient arrives at a place of definitive care (hospital with appropriate antivenom etc).



IN HOSPITAL:

- **Maintain airway/breathing if impaired.**
- **Establish IV line, give IV fluid load.**
- **Admit for serial clinical observations and serial laboratory testing.** If clinical (including antivenom stocks) or laboratory facilities are inadequate, maintain PBI and arrange transfer or retrieval to an appropriate hospital. A suggested algorithm for country hospitals is provided on page 14.
- **Antivenom therapy** is indicated in most cases if there is any evidence of systemic envenoming detected by clinical observation or on laboratory testing. Always **consult early with clinical toxicology experts and the local Critical Care Referral Network** if in any doubt, preferably before commencing antivenom (**WCH 8161 7000 & ask for duty clinical toxicologist**).
- **Removal of PBI first aid:** The bandage should not be removed until the patient is fully assessed (clinical history, examination, laboratory tests performed and results assessed, and, if indicated, venom detection performed), stabilised (ABC, IV line in situ, IV fluid load) and if envenomed, treatment commenced (appropriate type and dose of IV antivenom given). In a significant number of patients, initial clinical and laboratory examination will be normal, with no indication of systemic envenoming. Such patients **do not** require antivenom at this time and the PBI first aid should then be removed. 1 hour later they should be fully re-evaluated, including repeat laboratory testing, or earlier if symptoms develop. Do not leave PBI in place for long periods of time, especially in a well patient. **NEVER** remove PBI first aid prior to assessing the patient, stabilising the patient, or if unable or unwilling to commence appropriate antivenom therapy.

Clinical evidence of envenoming:

- Any degree of **paralysis** (e.g. ptosis, ophthalmoplegia, respiratory distress).
- **Excessive bleeding** (bleeding gums, prolonged bleeding from venepuncture sites or other wounds, including the bite site).
- Period of **unconsciousness** or **fitting**, or a **collapse** or **cardiac arrest**.
- Oliguria, anuria, or myoglobinuria.
- General symptoms such as headache, vomiting, abdominal pain, but beware of these in isolation (i.e. anxiety reaction only). If all other clinical and laboratory indicators are normal, such general symptoms alone are not usually sufficient reason to commence antivenom therapy.

Laboratory evidence of envenoming:

- Laboratory tests to monitor for envenoming should include coagulation studies (INR, aPTT, fibrinogen, d-dimer), FBC/CBP, EUC and CK.
- If initial tests are normal (pre PBI removal), repeat testing 1 hr post-removal of PBI and then at about 6 & 12 hours post-bite, or more urgently if the patient develops clinical evidence suggestive of envenoming.
- Where laboratory testing is not rapidly accessible a 20 min. whole blood clotting test (20WBCT) may be performed but should not delay arrangements for transfer of the patient. (20WBCT; put 5-10 mls venous blood into a clean **glass** test tube and check if clotted at 20 mins; perform a parallel control on normal blood; see page 15 for details).
- An INR>2 usually indicates a coagulopathy (unless patient is on warfarin).
- Myoglobinuria or a significantly raised CK (>1,500IU/l) indicates myolysis.
- Abnormally raised creatinine or urea or oliguria/anuria indicates renal damage.
- Cut away bandage over bite site and swab for venom detection (**CSL Snake Venom Detection Kit**). Best sample for venom detection is bite site swab.

Snake Venom Detection Kit (SVDK):

- **Only use the SVDK** to choose which antivenom is appropriate. **NEVER** use it to determine if there is envenoming, or exclude snakebite.
- **Best sample is a bite site swab** (moistened) - Cut away bandage over bite site and swab for venom detection. Collect at earliest opportunity after presentation to hospital and store sample for later testing, if indicated. **ONLY** if systemic envenoming, may alternatively use urine; blood may be unreliable. Test takes up to 25mins, ideally performed in a laboratory (see page 25-27 for method).
- **A positive result in an ENVENOMED patient indicates;** definite snakebite, type of antivenom to use (if required), **BUT** is not a sole indication to give antivenom. Give antivenom if there is clinical &/or laboratory evidence of significant systemic envenoming (see above). **NOTE:** positive venom detection from the bite site does **NOT** imply systemic envenoming and is not in itself an indication for antivenom.

- **A negative result** does **NOT** exclude either a snakebite or systemic envenoming.
- Always confirm SVDK result by comparing with result from diagnostic algorithms (see page 12) combined with knowledge of snakes in region.

ANTIVENOM (AV) THERAPY: Treatment of choice for systemic envenoming. Use monovalent in preference to polyvalent if the identity of snake is known (use snake venom detection kit, with confirmation using diagnostic algorithms combined with knowledge of snakes found in region, plus expert advice if unsure or if conflict between SVDK and diagnostic algorithm results). Do not overlook polyvalent antivenom as backup if insufficient monovalent antivenom available.

- **Always give IV, diluted** up to 1:10, depending on size of patient and volume of antivenom. Always have **adrenaline ready** drawn up or in syringe pump, in case of anaphylaxis. Commence antivenom infusion slowly, increasing rate if no adverse reactions, aiming to give whole initial dose over 15-20mins.
- Dosage varies with type of antivenom, type of snake, number of bites, but **children require same dose as adults**.
- Starting dose for major **brown snake bite** is 2 vials§ of Seqirus Brown Snake AV. For some smaller rural hospitals, the recommended stock level is 2 vials, to be given in life threatening situations, whilst supplementation of stocks from another hospital, plus retrieval are being arranged.
- Starting dose for major **tiger snake bite** is 2 vials of Seqirus Tiger Snake AV (some large races of tiger snake may require a higher initial dose). For some smaller rural hospitals, the recommended stock level is 2 vials, to be given in life threatening situations, whilst supplementation of stocks from another hospital, plus retrieval are being arranged.
- Starting dose for **taipan bite** is 1 vial of Seqirus Polyvalent or Taipan AV, but in some circumstances a higher initial dose may be appropriate (seek expert advice).
- Starting dose for **mulga snake bite** is 1 vial of Seqirus Black Snake AV.
- Starting dose for major **red bellied black snake bite** is 1 vial of Seqirus Tiger Snake AV, although Seqirus Black Snake AV may also be considered.
- Starting dose for major **death adder bite** is 1 vial of Seqirus Death Adder AV, but in some circumstances a higher initial dose may be appropriate (seek expert advice).
- One vial of Seqirus Polyvalent Snake AV is equivalent to at least 1 vial of relevant monovalent AV, as above. In most cases an initial dose should be 1 vial.
- Further doses of antivenom may rarely be required in major cases.
- If the patient has had 25mls or more AV, consider a course of prophylactic oral steroids.

FOLLOW UP: Always ensure snakebite patients are followed up adequately, particularly if given AV, watching especially for serum sickness.

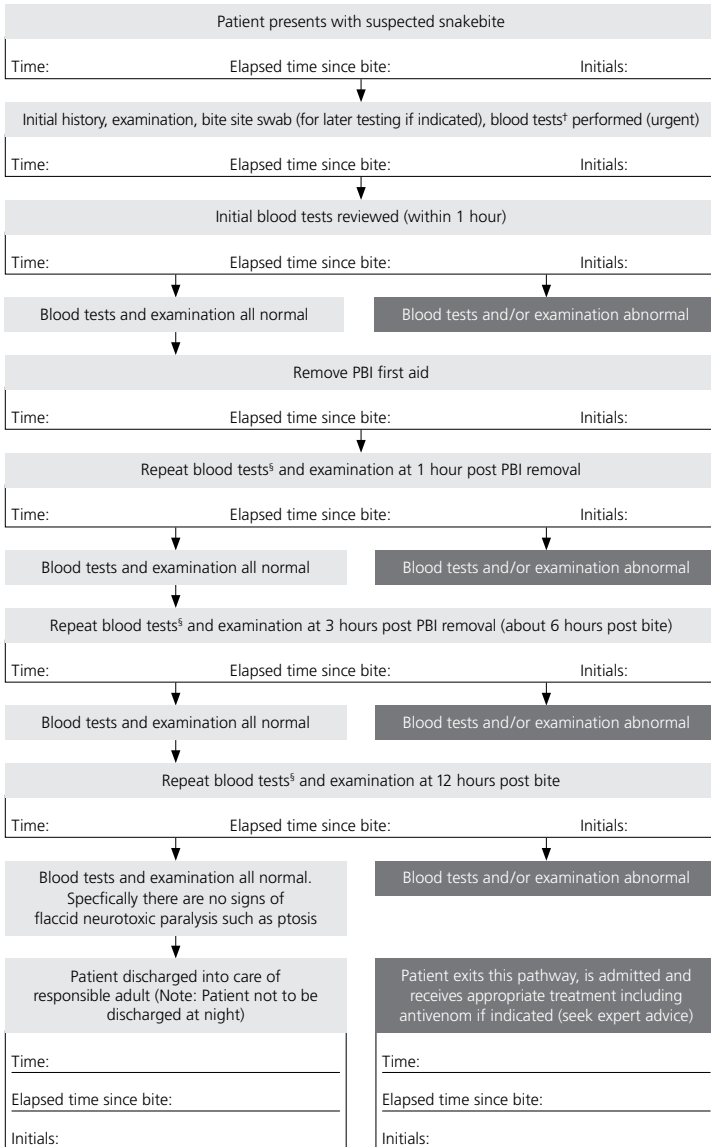
Snakebite Clinical Pathway

Clinical pathway for suspected & confirmed snake bite:

All cases should be observed with serial blood testing and serial examination for 12 hours to exclude systemic envenoming using the following pathway.¹⁰ Frequent routine observations should continue throughout the 12 hour observation period (in addition to the formal testing noted below).

Surname: _____
 First name: _____
 DOB: _____
 UR: _____

Date: _____ Doctor: _____ Signature: _____



† Recommended initial laboratory investigations:
 Coagulation tests (INR, aPTT, FDP/d-dimer), FBC (+ blood film), CK, UEC.
 Swab bite area for snake venom detection (SVDK to be performed if there is clinical/laboratory evidence of envenoming)*

‡ Recommended subsequent laboratory investigations:
 Coagulation tests (INR, aPTT, FDP/d-dimer), FBC, CK, UEC

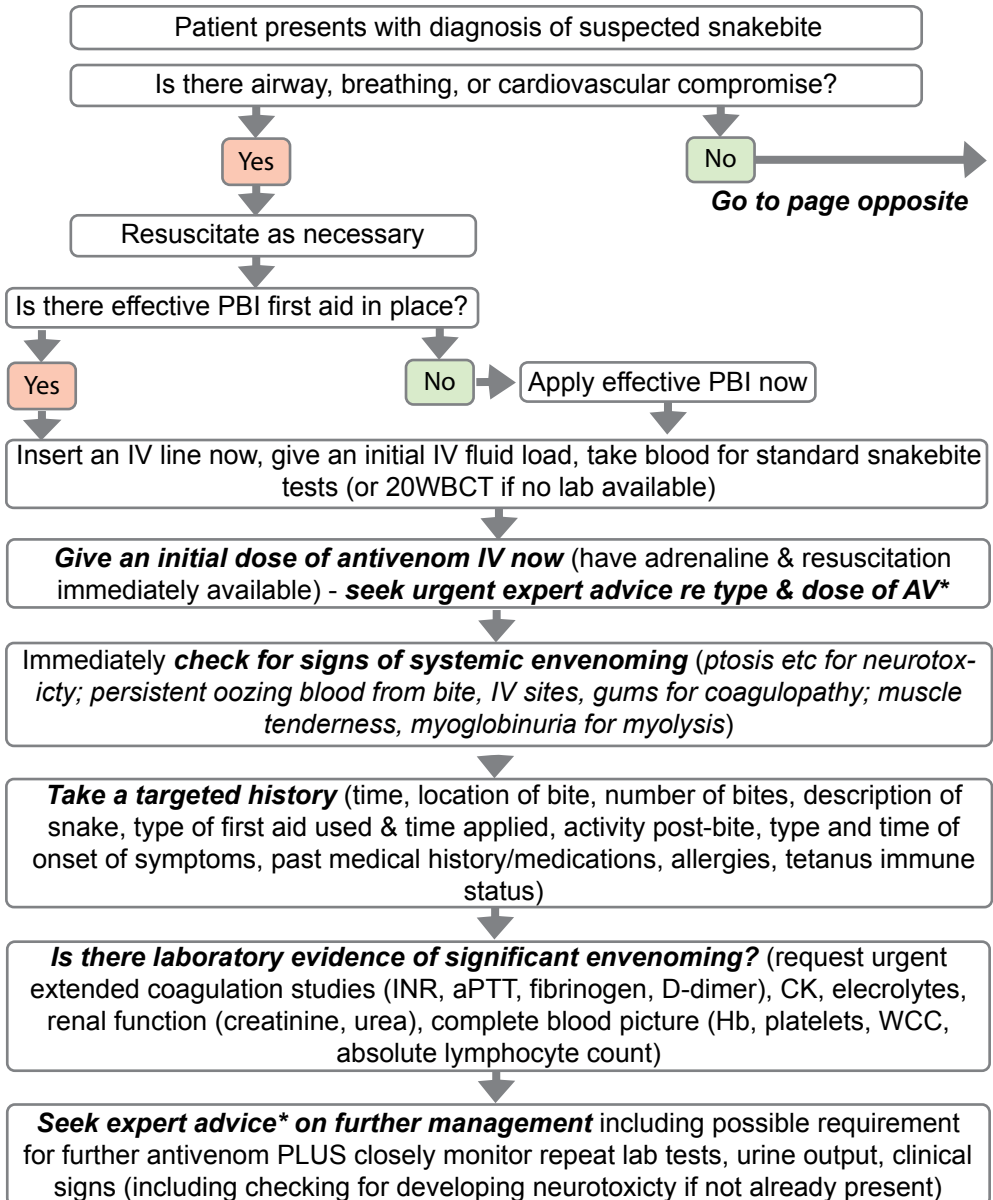
Examination should include testing for flaccid neurotoxic paralysis, especially repeated testing for ptosis, ophthalmoplegia (especially failure of lateral & upward gaze) and vigilance for bulbar weakness (poor cough, gag, drooling), and limb weakness

*Venom detection using the SVDK can assist in the choice of the appropriate AV if AV therapy is clinically indicated. SVDK should not be used as a screening test to determine whether or not a patient has been bitten by a snake. Many health services now have a policy of performing SVDK only if there is clinical or laboratory evidence suggestive of developing envenoming

This clinical pathway is copyright © Prof. Julian White, but may be freely copied and used by health professionals for use in managing snakebite patients.

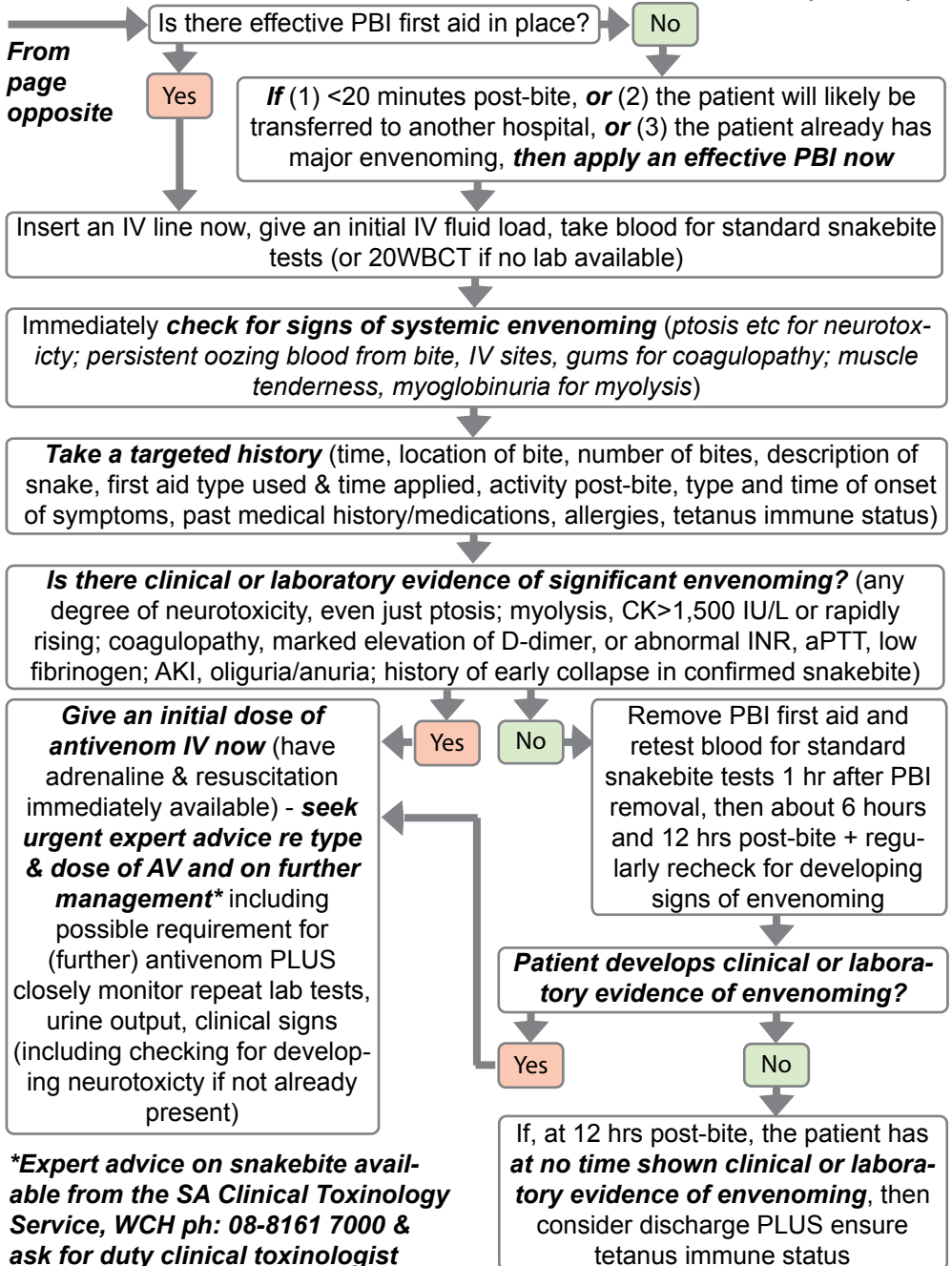
URGENT HOSPITAL SNAKEBITE CARE ALGORITHM

URGENT HOSPITAL MANAGEMENT OF SNAKEBITE



***Expert advice on snakebite available from the SA Clinical Toxinology Service, WCH ph: 08-8161 7000 & ask for duty clinical toxicologist**

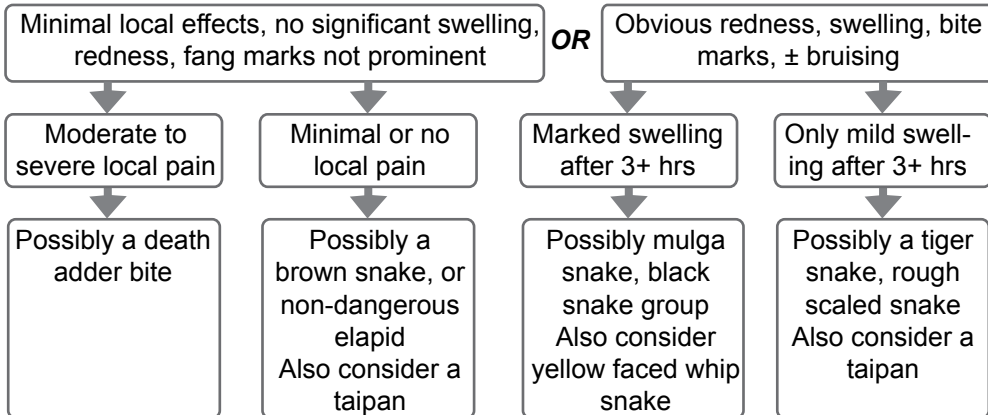
URGENT HOSPITAL MANAGEMENT OF SNAKEBITE (cont'd)



DIAGNOSTIC ALGORITHM FOR AUSTRALIAN SNAKEBITE Δ

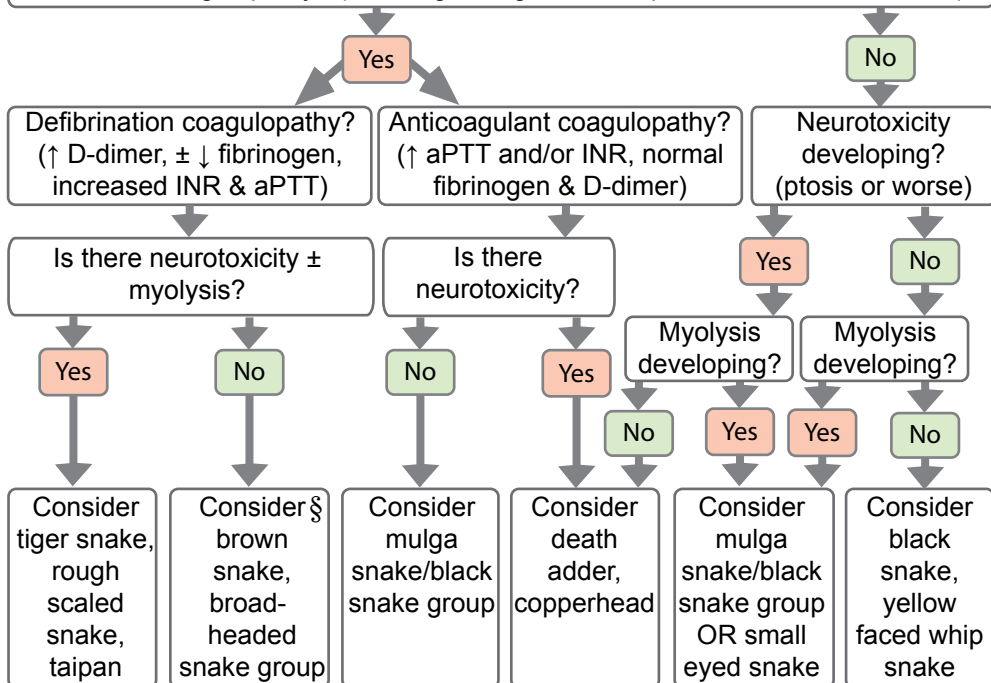
1. Determine likely snakes in the region where patient was bitten (see guide pgs 768,80,82) and use that to consider most likely snake options in algorithms below

2. LOCAL EFFECTS - Examine the bite site



3. SYSTEMIC EFFECTS - Check for coagulopathy, myolysis & neurotoxicity

Is there a coagulopathy? (bleeding bite, gums, venepunctures or lab evidence)



Diagnostic algorithm copyright © Prof. Julian White 2018

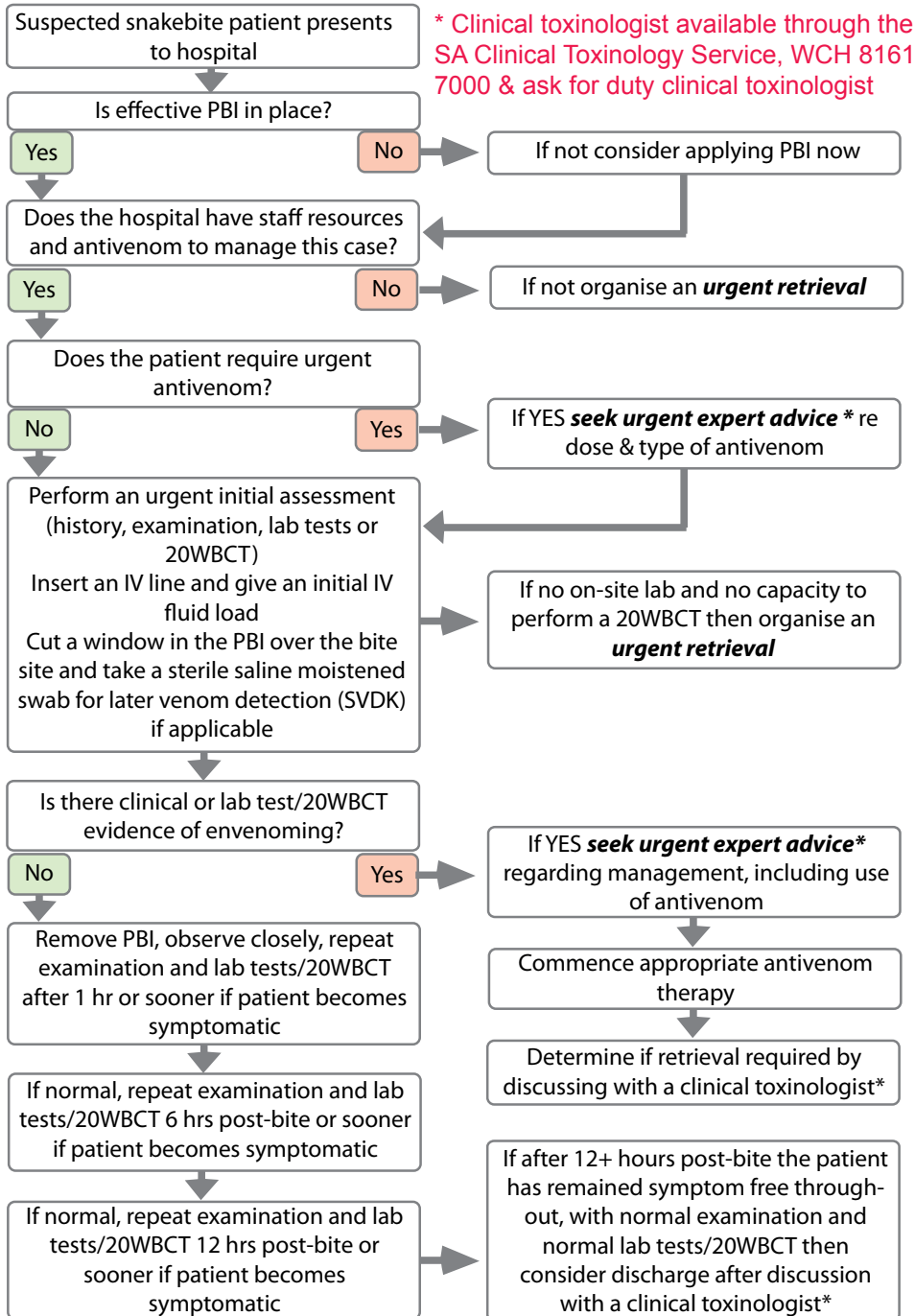
Δ Diagnostic algorithms for snakebite are only likely to be useful in a patient with evidence of envenoming and cannot cater for atypical presentations. If in doubt seek expert advice from the SA Clinical Toxinology Service (WCH 8161 7000).

§ consider possibility this is a tiger snake bite with early envenoming showing initial coagulopathy only

MAJOR PATTERNS OF CLINICAL AND LABORATORY FINDINGS AFTER AUSTRALIAN SNAKEBITE

- 1. Defibrination coagulopathy (elevated D-dimer, ↑ INR, aPTT, ↓ fibrinogen).**
 No paralysis or myolysis. Bite site usually minimal or no pain, no significant swelling, bruising or redness, but there may be ooze of blood.
 Likely snakes: Brown snakes (all species except ringed brown snake) (genus *Pseudonaja*).
 Broad headed snakes, including Stephen's banded snake and pale headed snake (genus *Hoplocephalus*).
- 2. Defibrination coagulopathy + paralysis ± mild myolysis.**
 Bite site variable; there may be an ooze of blood.
 Likely snakes: Taipan & inland taipan (genus *Oxyuranus*).
- 3. Defibrination coagulopathy + paralysis + moderate to severe myolysis.**
 Bite site usually painful, with mild swelling, bruising, redness, there may also be an ooze of blood.
 Likely snakes: Tiger snakes (genus *Notechis*).
 Rough scaled snake (genus *Tropidechis*).
- 4. Moderate to marked myolysis (rapidly rising CK or >1500IU/l) + anticoagulant coagulopathy (↑ aPTT ± ↑ INR, fibrinogen normal, no raised FDP/XDP).**
 No paralysis (beware major myolysis mimicing paralysis). Bite site usually painful, often marked swelling, sometimes bruising. Persistent blood ooze not common.
 Likely snakes: Mulga snake, Collett's snake, spotted black snake, red bellied black snake (genus *Pseudechis*).
- 5. Moderate to marked myolysis (rapidly rising CK or >1500IU/l).**
 No paralysis (beware major myolysis mimicing paralysis) or coagulopathy. Bite site usually painful, often marked swelling, sometimes bruising. Persistent blood ooze not common.
 Likely snakes: Mulga snake, Collett's snake, spotted black snake, red bellied black snake (genus *Pseudechis*).
 Eastern small eyed snake (*Cryptophis nigrescens*).
- 6. Paralysis (postsynaptic; reverses with antivenom therapy) ± mild anticoagulant coagulopathy (↑ aPTT ± ↑ INR, fibrinogen normal, normal FDP/XDP).**
 No myolysis. Renal damage unlikely. Bite site often painful, but with little swelling, redness or bruising. Persistent blood ooze unlikely.
 Likely snakes: Death adders (genus *Acanthophis*).
- 7. General symptoms of envenoming (some or all of; headache, nausea, vomiting, diarrhoea, abdominal pain, dizziness, collapse).**
 No paralysis or coagulopathy; no or generally mild myolysis. Bite site usually painful, often marked swelling, sometimes bruising. Persistent blood ooze not common.
 Likely snakes: Red bellied black snake and mild bites by spotted black snake and Collett's snake (genus *Pseudechis*).
 Yellow faced whip snake and other large whip snakes (genus *Demansia*).

DECISION ALGORITHM FOR COUNTRY HOSPITALS DECIDING WHEN/IF TO TRANSFER A PATIENT WITH SUSPECTED SNAKEBITE



INSTRUCTIONS FOR PERFORMING THE 20 MINUTE WHOLE BLOOD CLOTTING TEST (20WBCT)

Currently the only bedside clotting test that has been scientifically validated to detect coagulopathy in snakebite patients is the 20WBCT.

1. The tube used to test the 20WBCT must be made of glass (NOT plastic) and must be clean and dry. Ideally, it should also be new. Exposure to washing detergent or soap will stop the blood from clotting, a so-called false-positive test result. We recommend that you use only disposable glass tubes. If disposable glass tubes are not available, you can use clean glass antibiotic vials after they have been boiled with salt only, never with detergent, soap or other chemicals, and dried afterwards with hot air.

2. Place about 2-5mls of venous blood in the glass tube.

3. Let it stand for 20 minutes. The glass tube with blood must be left undisturbed for 20 minutes. The tube must not be flicked or agitated whilst waiting.

4. At 20 minutes gently invert/tip the glass tube checking for the presence of a blood clot. Sometimes, after 20 minutes, a thin layer of serum appears on top of the clot, and this serum may run slightly down the side of the tube when gently inverted. If the tube is left for 30 minutes or longer after the blood has been placed in it, the clot may start to break down, leading to a false-positive result. Therefore, try to read the test at exactly 20 minutes.

4A. Clot present = negative test (no coagulopathy present). On gently inverting/tipping the tube the blood does not down the tube because it is clotted. If a clot has formed after 20 minutes (a negative test), the clot will stop the whole blood from running freely down the side of the tube when gently inverted, although the serum may run down the tube. In this case, you can ignore the serum on top of the clot.

4B. Clot absent = positive test (coagulopathy present). On gently inverting/tipping the tube the blood runs down the tube because it is still liquid, unclotted.


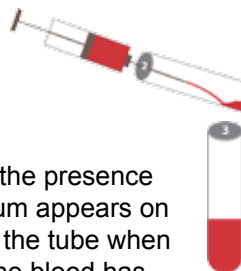
5. If there is any uncertainty about the result of the 20WBCT, a separate 20WBCT ought to be done in parallel using blood from a healthy individual to prove that normal blood will clot after 20 minutes. This is the negative control.

6. If blood from a healthy individual clots after 20 minutes, the finding that blood from a snakebite patient does not clot is a very significant positive test result.

7. If blood from a healthy individual clots after 20 minutes, the finding that blood from a snakebite patient also clots after 20 minutes implies that the patient does not have coagulopathy at that time.

8. If blood from a healthy individual does not clot after 20 minutes, it will be difficult to interpret the result of the 20WBCT from the patient. The most common problem here is contamination of the tube with washing detergent or soap.

9. Note that the 20WBCT must be repeated at regular intervals after the initial test to detect late-onset coagulopathy.

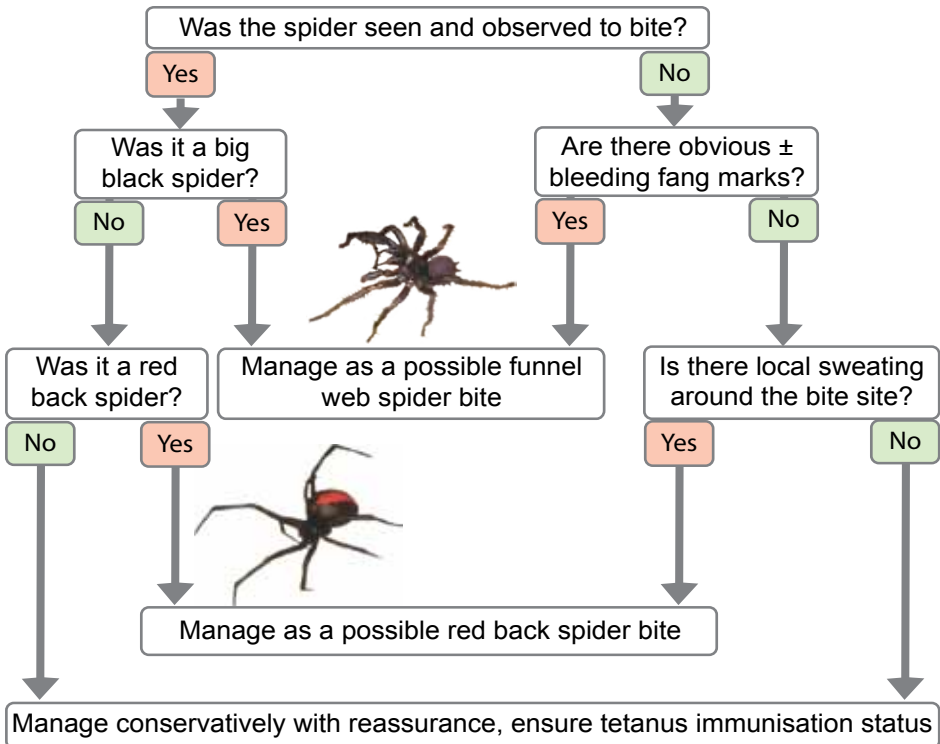


MANAGING SPIDERBITE CASES AND DECIDING ON THE LIKELY TYPE OF SPIDER OR COURSE OF MANAGEMENT

Spiders are very common. Spiderbite is common, far more frequent than snakebite, but most spiderbites are trivial and require no treatment. Two groups of spiders have the potential to cause significant envenoming; red back spiders and their kin, and funnel web spiders and their kin. It follows that the most important decision in managing a spiderbite is to decide if the spider is a possible funnel web spider (“big black spider”), a red back spider, or something else.

A diagnostic algorithm has been developed to assist in making this decision. Like all such algorithms, it cannot cover all situations and is meant as a guide only, not an absolute indicator in every situation.

To further assist in determining the type of spider, the diagrams opposite illustrate some key features that distinguish mygalomorph spiders (such as funnel web spiders and trapdoor spiders) from araneomorph spiders (most other types of spiders, including the red back spider).



Algorithm copyright © Prof. Julian White 2018



Huntsman spider



White tailed spider



Wolf spider



Black house spider

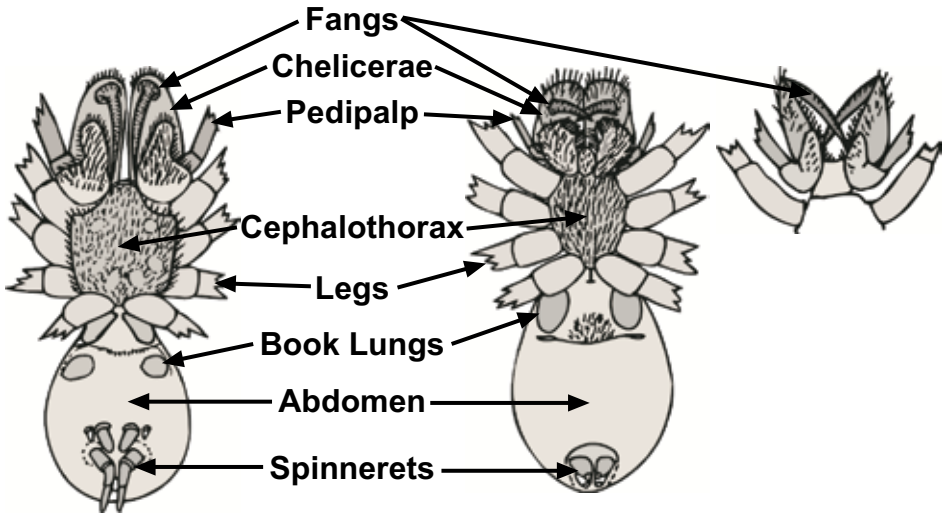


Orb weaving spider

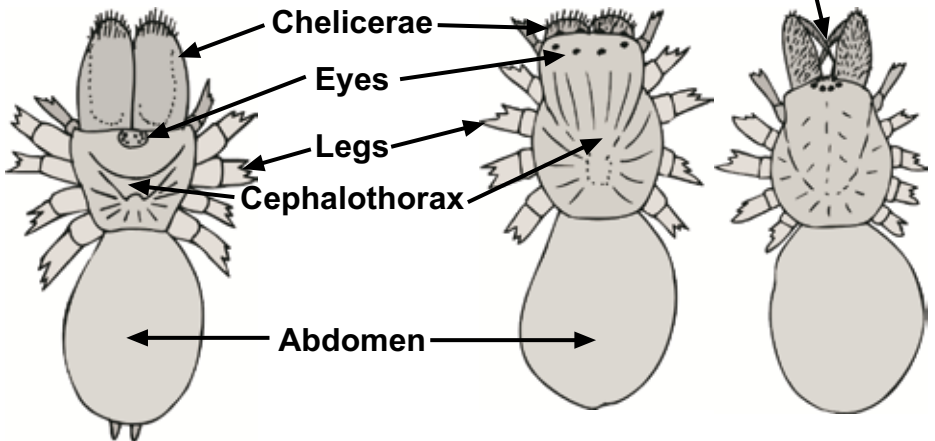
MYGALOMORPH SPIDERS

ARANEOMORPH SPIDERS

Ventral Surface (underside)



Dorsal Surface (topside)



RED BACK SPIDER

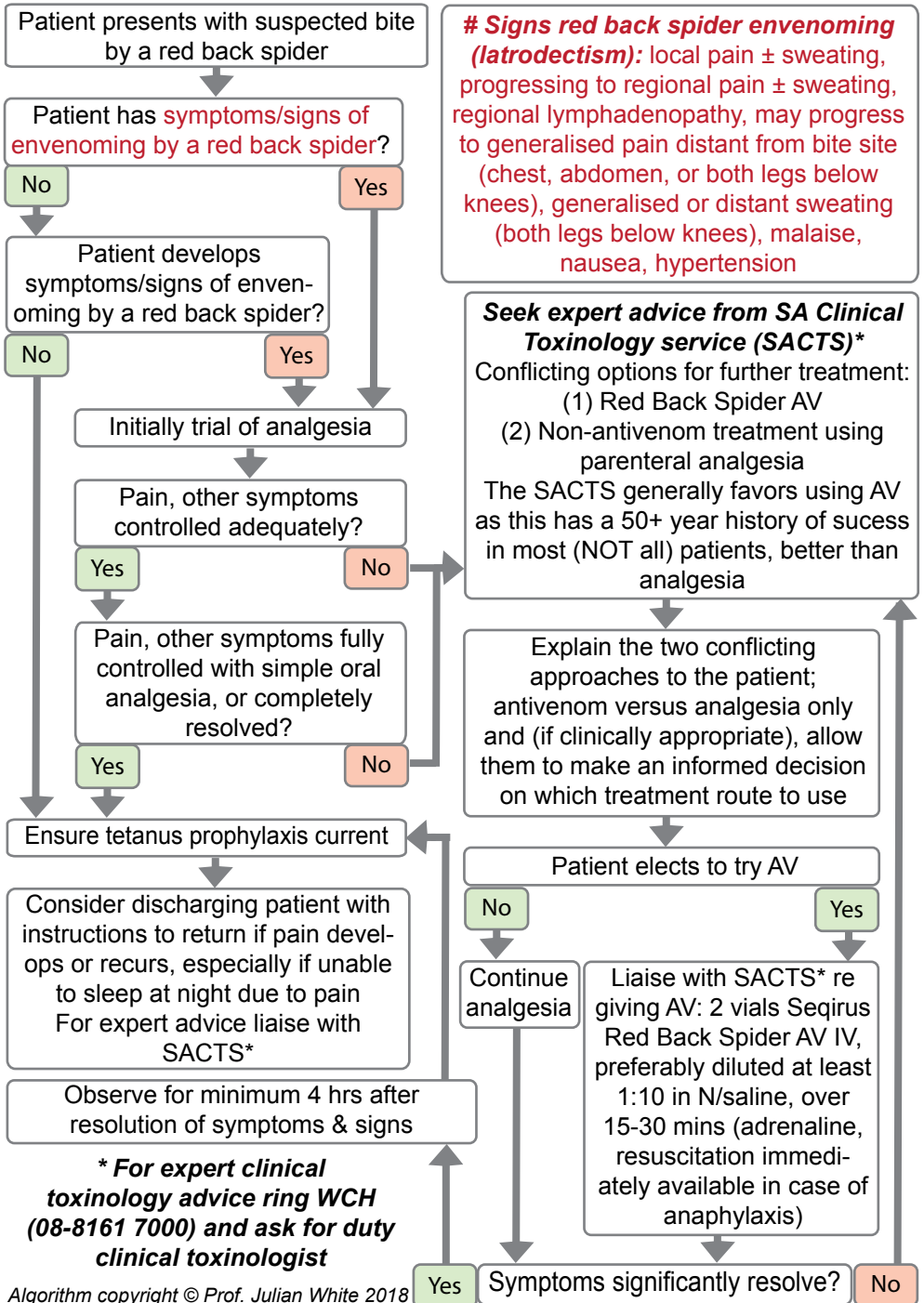
EMERGENCY OVERVIEW OF RED BACK SPIDER BITE

Red back spider bite is common but very unlikely to prove lethal, even if untreated.

- **Significant envenoming may occur in less than 20% of cases**, but if left untreated, will result in several days of distress for the patient.
- **Only those patients who develop symptoms need assessment in hospital.** Those patients who present to hospital with no or minimal symptoms may be allowed home, but asked to ring or return if pain or other symptoms develop. Symptomatic patients should be fully assessed in hospital.
- **In those patients who do develop significant envenoming:**
 - The **bite is often felt**, usually as a mild sting.
 - A variable time later they **develop local pain** which becomes severe and is sometimes associated with local sweating.
 - The bite site is quite variable in appearance and there may be nothing to see.
 - The **pain becomes more severe and spreads** proximally, often causing pain/swelling of draining lymph nodes.
 - They **develop** regional or generalised pain, usually severe, often with **sweating** and hypertension and malaise. There may be nausea.
 - The **pain may mimic** acute abdomen or cardiac chest pain.
 - Left **untreated** with antivenom, the **symptoms may persist** for days or longer.
 - **In delayed presentation**, the pain sometimes alters to become more prominent in the legs and feet, often described as burning (even if the bite was elsewhere).
- There are **no** useful or diagnostic **laboratory tests** for red back spider bite.
- **In all cases with significant regional or systemic envenoming, Seqirus Red Back Spider AV should be considered** and it *may* be justified, **if initial appropriate analgesia has proved ineffective**. A single study published in 2014 concluded that this AV is ineffective, but there are arguably issues with this study and it should not be used to determine clinical practice in SA (see page 64 for further discussion).
- **Antivenom treatment**
 - **Give 2 vials, preferably IV.** For IV administration dilute the antivenom at least 1:10 in normal saline. Always have adrenaline and full resuscitation available in case of anaphylaxis, but premedication is not required.
 - Wait 2+ hours. If incomplete resolution of symptoms, consider giving a further 2 vials IV.
 - Wait 2 hours. If incomplete resolution of symptoms seek expert advice.
- **If antivenom therapy is unsuccessful** for red back bite, it may be because not enough has been given.
- **Antivenom may be effective days after the bite** (possibly longer but unproven).
- **If the symptoms suggest red back bite**, but there is no spider identified or uncertain history of a bite, still consider giving antivenom, preferably after seeking advice.
- **If in any doubt ring for advice; WCH Clinical Toxinology Service, 8161 7000 & ask for the duty clinical toxinologist.**



ALGORITHM FOR MANAGING RED BACK SPIDERBITE



FUNNEL WEB SPIDERS

EMERGENCY OVERVIEW of FUNNEL WEB SPIDER BITE

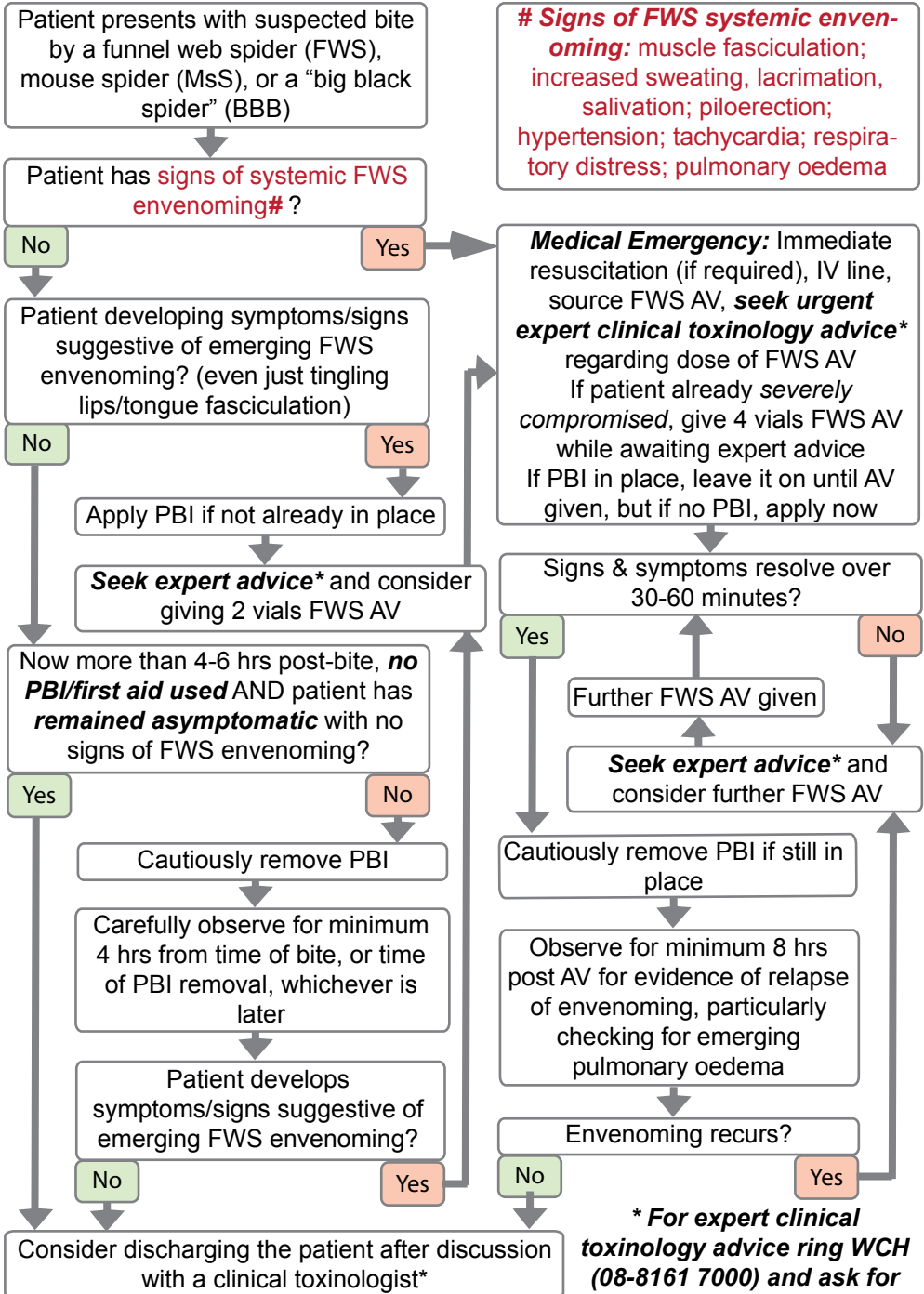


Sydney funnel web spider, *Atrax robustus* - male on left, female on right

There are three species of funnel web spider found in SA, all restricted to a distribution from the southern Mount Lofty ranges to the southern Flinders Ranges. All are rarely encountered. None have caused significant bites so far, but experience with related species in eastern Australia suggests the SA species might be capable of causing major envenoming.

- **Funnel web spider bite is potentially rapidly lethal.**
- All possible funnel web spider bites (including “big black spiders” that could be funnel web spiders) should be **managed as a medical emergency**.
- However, the **majority of bites will be minor**, not requiring antivenom.
- If the patient has presented within 4 hours of the bite or has effective first aid in place, **insert an IV line**.
- **Do not remove first aid until ready to treat with antivenom.**
- **Bite is usually painful** and fang marks are present in most cases.
- **Symptoms and signs of systemic envenoming**
 - Perioral tingling and tongue fasciculation.
 - Increased salivation, lachrymation, piloerection, sweating.
 - Nausea, vomiting, headache.
 - Hypertension, tachycardia.
 - Dyspnoea, pulmonary oedema (may occur early or be delayed several hours).
 - Irritability, decreased conscious state, coma.
- There are **no diagnostic tests** for funnel web envenoming.
- **If there are any symptoms of systemic envenoming give 2 vials of Seqirus Funnel Web Spider Antivenom IV** (in SA this antivenom is held at RAH & WCH).
- **If the envenoming is severe**, with dyspnoea, pulmonary oedema or altered conscious state, **give 4 vials** of Seqirus Funnel Web Spider Antivenom IV.
- **Be prepared to give more antivenom** until major symptoms resolved. 8 vials may be required in severe bites.
- **If in any doubt ring for advice; WCH Clinical Toxinology Service, 8161 7000 & ask for the duty clinical toxicologist.**

ALGORITHM FOR MANAGING FUNNEL WEB SPIDER BITE



MARINE VENOMOUS ANIMALS

EMERGENCY OVERVIEW OF MARINE ENVENOMING

Marine envenoming and poisoning is common.

Stingrays.

Cause both local tissue injury and local envenoming (pain).
Local tissue injury may be severe and take precedence in management.
Hot water immersion helps reduce pain.
Persistent pain may require local anaesthetic or regional nerve block.
Ensure tetanus prophylaxis.
Consider prophylactic antibiotics in cases with significant local tissue injury.
There is no antivenom available.

Spiny venomous fish (stonefish, bullrout etc.).

Local pain predominates.
Hot water immersion helps reduce pain.
Persistent pain may require local anaesthetic or regional nerve block.
Ensure tetanus prophylaxis.
Consider prophylactic antibiotics in cases with significant local tissue injury.
There is no antivenom available, except for stonefish stings.

Blue ringed octopus.

Most bites are minor, but potentially lethal.
Bite may be painless.
In significant cases, rapid development of systemic envenoming which may include: Perioral tingling. Progressive generalised weakness/paralysis. Respiratory paralysis. Hypotension.
Maintain airway, respiration (intubate, ventilate), give IV fluids \pm pressors to control hypotension. No antivenom is available.

Medically significant jellyfish stings

Sting is usually painful. There may be weals, erythema or even blistering.
Severe allergic reactions possible.
Hot water immersion at 45 degrees Celsius or equivalent hot shower is the best method of pain relief. Treat symptomatically.
Antivenom is only available for stings by the Northern Australian box jellyfish species (*Chironex fleckeri*), which does not occur in SA waters. Irrigating the sting with copious vinegar is the recommended first aid for this species (though some researchers advise against the use of vinegar); do not use PBI.

Blue bottle stings (Physalia spp.)

Sting is usually painful. Linear raised erythematous mark.
Hot water immersion at 45 degrees Celsius or equivalent hot shower is the best method of pain relief.
Occasionally rashes may last for a few days and bullous reactions occur rarely.
No antivenom is available.

If in any doubt ring for advice, WCH Clinical Toxinology Service, 8161 7000 & ask for the duty clinical toxicologist.

PROTOCOL FOR MANAGING A CASE OF SNAKEBITE

BASIC INFORMATION

Venomous snakebite is a medical emergency, potentially life threatening, and is NOT a simple matter of just giving antivenom. **EXPERT ADVICE** is available from the **SA Clinical Toxinology Service (WCH 8161 7000 & ask for duty toxinologist)**.

A considerable number of snakebites do not result in significant illness, and do not require Antivenom, but **ALL probable snakebites should be admitted** for observation at least for 12+ hrs or overnight, as some serious effects may be delayed. Followup review may be indicated, depending on clinical circumstances. As with all injuries causing skin penetration, ensure the patient has adequate tetanus immune status before discharge, but do NOT give a tetanus booster IM injection until any coagulopathy has either been resolved or excluded.

PROTOCOL FOR MANAGING A CASE OF SNAKEBITE IN A HOSPITAL WITH ANTIVENOM AVAILABLE

[1] [a] **Possible or definite snakebite: GO TO Section [2].**

OR

[b] **The patient presents unwell, diagnosis uncertain.** There is a history of possible exposure to snakes (i.e. walking in long grass etc), and the patient has any of the following; loss of consciousness, convulsions, headache, vomiting, weakness or paralysis (initially ptosis, diplopia, slurred speech), dark urine, bleeding, renal failure; consider snakebite: **GO TO Section [7]** for advice on confirming snakebite as a diagnosis.

[2] [a] **The patient is unwell, possibly envenomed. GO TO Section [3]** (below).

OR

[b] **The patient is well, no apparent envenoming. GO TO Section [6].**

[3] **Management of the envenomed or possibly envenomed patient:**

[i] **Urgent Treatment:**

Respiratory failure and/or circulatory failure: follow standard Advanced Life Support Protocols. Note that in advanced neurotoxicity with impending loss of airway protection or respiration, external respiratory support is crucial.

Insert an IV line (normal saline, give initial IV fluid load, about 500-1,000ml over 2-3hrs in adults, less for children, then run at maintenance, keep the patient fasted). If possible insert long line in cubital fossa or similar, to allow frequent blood sampling and avoid the need for further venepunctures. Avoid subclavian, femoral and jugular vessels, as uncontrollable haemorrhage may occur if there is a coagulopathy.

If profound hypotension, IV volume restoration/electrolyte solution. A degree of hypertension may be encountered which usually resolves.

If patient already has severe envenoming, apply pressure bandage/ immobilisation first aid (remove when initial antivenom therapy is completed).

Blood samples:

- coagulation studies (PT/INR, aPTT, Fibrinogen, XDP/d-dimer/FDP)
- complete blood picture (CBP/FBE)
- electrolytes, renal function, CK
- **IF** no laboratory testing immediately available then perform a 20 minute whole blood clotting test (20WBCT; in clean glass test tube; page 15).

Avoid venepuncture in sites where bleeding may be difficult to control (i.e. femoral, neck, subclavian).

Anaphylaxis due to allergy to venom is occasionally seen: (i.e. in reptile keepers). Treat with IV adrenaline infusion (see section 5) OR IM adrenaline (initial dose 0.25-0.5 mg.). For paediatric dosages see section [5] [vi].

[ii] History:

- was a snake seen to bite (?multiple bites) OR were the circumstances such that a bite might have occurred?
- when did the patient get bitten (elapsed time)?
- description of snake if possible (colour, length)
- geographic place that the incident occurred (snakes in area)
- timing and type of first aid and activity after the bite
- type and timing of symptoms; specifically ask about headache, nausea, vomiting, abdominal pain, blurred or double vision, slurring of speech, muscle weakness, respiratory distress, bleeding from the bite site or elsewhere, passing dark or red urine, local pain or swelling at the bite site, pain in lymph nodes draining the bite area (axilla, or groin), loss of consciousness, convulsions.
- relevant past history; specifically ask about allergy or past exposure to antivenom, atopic (allergy) history, renal, cardiac, or respiratory disease, tetanus immune status and medications (eg. anticoagulants etc).

[iii] Examination:

- assess patient status looking for:
- evidence of a bite (if an adequate first aid bandage is in place cut first aid bandage away from over bite site, keeping bandage from area adjacent to skin, DO NOT WASH WOUND, but consider swabbing for venom detection; see Section [4] for technique of venom detection), and look for evidence of multiple bites, or venom movement (swollen or tender draining lymph nodes),
- neurotoxic paralysis (ptosis, diplopia, dysarthria, drooling, fixed dilated pupils, limb weakness, decreased or absent deep tendon reflexes, respiratory distress),
- coagulopathy (bleeding from bite site, gums, or elsewhere),
- muscle damage (muscle tenderness, pain on movement, weakness, brown or red urine indicating myoglobinuria).

[iv] Determine if there is systemic envenoming.

If there is then ANTIVENOM therapy will probably be needed.

Systemic envenoming is present if there is one or more of the following:

- neurotoxic paralysis (e.g. ptosis, ophthalmoplegia, limb weakness, respiratory effects)

- significant coagulopathy (e.g. unclottable blood, INR>2, prolonged bleeding from wounds, venepunctures etc.; see Section [8] for details on coagulopathy and its management)
- significant myolysis (myoglobinuria (see section [7] [ii]), significantly raised CK)
- unconsciousness or convulsions or cardiac collapse if definite snakebite
- early non-specific symptoms such as headache, vomiting, abdominal pain may indicate developing envenoming, BUT beware of these as purely manifestations of anxiety rather than envenoming. If these are the only evidence of envenoming then be cautious in deciding if antivenom is required.

If systemic envenoming is present, consider ANTIVENOM therapy; see Section [5] for guide-lines on use and techniques of administration.

[vi] **Ongoing care:**

Should include; constant nursing care, with specific instructions to look for evidence of developing paralysis (ptosis, diplopia); monitor urine output, and if in doubt then catheterise; serial respiratory function (FVC, O₂ saturation or expired CO₂); check and update tetanus immunisation status (once coagulopathy resolved); avoid unnecessary venepunctures.

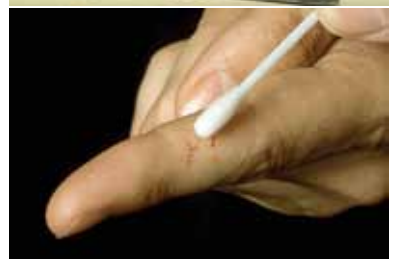[vii] **Once situation is stabilised** it may be possible to remove all first aid. However, if the patient has severe envenoming and will require transfer to another hospital, or if there will be a delay in obtaining further supplies of antivenom, consider leaving first aid in place longer.

[4] **Venom Detection using the Seqirus Venom Detection Kit (SVDK):**

[i] The SVDK should not be used to determine if a snakebite is a likely diagnosis. The only purpose of the SVDK is to determine best choice of antivenom, should antivenom be indicated on clinical or laboratory grounds.

[ii] The SVDK is designed to detect very small amounts of snake venom, and indicate which type of venom is present, corresponding to one of the 5 monovalent antivenoms. It does not necessarily indicate if envenoming has occurred. **A positive SVDK does NOT necessarily indicate that the patient needs antivenom therapy.**

[iii] The SVDK comes in a kit including three separate test well strips, each in protective foil, but only one set of instructions, reagents and accessories. It must be kept refrigerated, though if in a lab at 22°C, it can be left out of the fridge for the 20-25mins required to perform the test.



[iv] **The best sample is a swab from the bite site.**

Take an unused sample diluent bottle (currently yellow top) and use finger nail to lever off the dropper cap. Moisten the swab stick provided, in the solution in the bottle. Rub the swab firmly over the bite site and adjacent skin. Place the end of the swab back in the solution in the bottle and twirl around for a few moments to get venom into solution. Then proceed to use the kit as indicated in the instructions.



A positive result is indicated by a colour change (to blue) in one of the first five wells plus the positive control well (well 7), within 10 minutes in the last stage of the test, so watch all tubes carefully throughout this last 10 min. period. If one tube changes colour, all will do so eventually, but only the first tube to change is relevant.

If you get a positive result this usually indicates;

- (i) that venom was present on the skin (for a skin swab),
- (ii) the type of snake involved,
- (iii) the appropriate monovalent antivenom to use should this be needed.

IT DOES NOT INDICATE SYSTEMIC ENVENOMING HAS OCCURRED AND IS NOT AN INDICATION FOR ANTIVENOM THERAPY. EQUALLY A NEGATIVE RESULT DOES NOT EXCLUDE SNAKEBITE. See notes on each type of snake for further guidance on interpretation.

Be aware that false positives from bite site swabs, though rare, are possible.

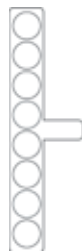- [v] **If the patient has evidence of systemic envenoming and the bite site is not available** for testing (i.e. been washed, or not apparent), then URINE is worth testing for venom. See kit instructions for dilutions, if necessary. Do not test urine unless the patient has evidence of systemic envenoming. Do NOT try and use the SVDK test on urine as a method of proving or excluding snakebite. Urine can give false positives for venom, especially brown snake venom. A positive SVDK for brown snake venom, in the absence of clinical or laboratory evidence of envenoming, such as coagulopathy, in nearly all cases should be considered a false positive and therefore of no diagnostic value.

- [vi] **Blood has proved an unreliable** sample for venom testing with the SVDK, giving both false positives and false negatives. It is not recommended for use with the SVDK.

CSL Snake Venom Detection Kit



Weak positive well 1 (cross-linkage effect; not relevant)
 Strong positive well 3 = mulga snake
 Weak positive well 5 (cross-linkage effect; not relevant)
 Negative control well (5)
 Positive control well (7)
 Actual SVDK result in a case of mulga snake bite.



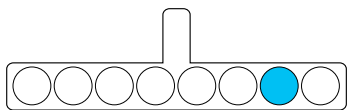
Well 1 Tiger snake venom
 Well 2 Brown snake venom
 Well 3 Mulga snake venom
 Well 4 Death adder venom
 Well 5 Taipan venom
 Well 6 Negative control
 Well 7 Positive control
 Well 8 Blank well

COMMON PATTERNS of SVDK VENOM DETECTION RESULTS

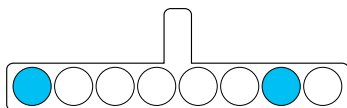
WELL NUMBER:

1 2 3 4 5 6 7 8

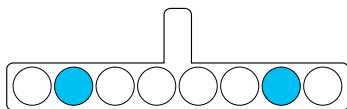
DIAGNOSTIC PATTERN:



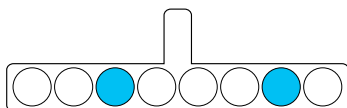
Only well 7 positive: No snake venom detected. This result does not exclude snakebite.



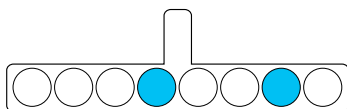
Wells 7 & 1 positive: If systemic effects include defibrination, paralysis \pm myolysis, suggests *tiger snake* or *rough scaled snake bite*. If systemic effects defibrination only, consider bite by *broad-headed, pale-headed* or *Stephen's banded snake*. If systemic effects are confined to paralysis, without defibrination, consider possibility of *copperhead bite*.



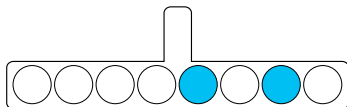
Wells 7 & 2 positive: Most likely a *brown snake bite*. If systemic envenoming develops, expect defibrination coagulopathy, \pm renal damage. Paralysis is unlikely and myolysis should not occur.



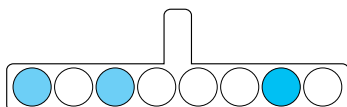
Wells 7 & 3 positive: Most likely a bite by a *mulga snake* (*king brown*) or *Collett's snake*; if systemic envenoming, expect myolysis, extensive swelling of bitten limb, \pm anticoagulant coagulopathy, \pm renal damage. **OR** Possibly a bite by a *red-bellied* or *blue-bellied* (*spotted*) *black snake*; if systemic envenoming, expect only mild myolysis, nocoagulopathy, paralysis or renal damage.



Wells 7 & 4 positive: *Death adder bite*; if systemic envenoming, expect post-synaptic paralysis, no coagulopathy, significant myolysis or renal damage.



Wells 7 & 5 positive: *Taipan* or *inland taipan bite*; systemic envenoming very likely. Expect defibrination coagulopathy, paralysis, \pm myolysis, \pm renal damage.



Wells 7, 1 & 3 positive: This pattern is sometimes seen with bites by several species. If a *copperhead bite*, if there is systemic envenoming, expect paralysis, without coagulopathy. If a *red-bellied* or *blue-bellied* (*spotted*) *black snake bite*, if there is systemic envenoming, expect only mild myolysis, no coagulopathy, paralysis or renal damage. If a *Collett's snake bite*, if there is systemic envenoming, expect myolysis, possibly anticoagulant coagulopathy, \pm renal damage.

[5] Antivenom (AV) Therapy:

[i] **Antivenom is the definitive treatment of envenoming**, and is potentially life saving but as it is currently refined horse serum, it is also potentially allergenic and therefore its use is not without risk. Therefore, **antivenom should only be used if there is systemic envenoming**. Overall less than 1 in 4 patients require antivenom therapy.

[ii] **See guide-lines in Section [3] [iv] for determining if systemic envenoming has occurred.**

IF THE TYPE OF SNAKE IS KNOWN then Monovalent Antivenom is preferred to Polyvalent (less hazardous, less side effects, less expensive). See section [4] for information on the use of Venom Detection to determine which type of antivenom to use. Check data sheet for the type of snake re particular guide-lines on use of antivenom (bites by some snakes may not need antivenom even if there is mild to moderate envenoming).

IF THE TYPE OF SNAKE IS NOT KNOWN (SVDK not available, or failed, or the patient requires Antivenom before a SVDK result is possible) then either Polyvalent Antivenom or an appropriate mixture of Monovalent Antivenoms should be used. The diagnostic algorithms in this document (page 12) may also assist in choice of antivenom. Please refer to advice sheet for your hospital to determine if there is an appropriate mix of two monovalent antivenoms for your area. In the greater Adelaide region, brown snake AV + tiger snake AV will cover all native species. In some areas north and west of Adelaide, where several diverse species of brown-coloured snakes are present, brown snake AV + black snake AV may be appropriate, providing the snake was definitely not a death adder and the area is not within the range of inland taipans. For some southern parts of York and Eyre Peninsulas, where there is a wide diversity of species, polyvalent AV may be required. In south east SA brown snake AV + tiger snake AV will cover native species.

[iii] **Antivenom (AV) administration:**

- Antivenom for snakebite should **always be given IV**, with all facilities **ready to hand to treat anaphylaxis** in the rare event that it should occur (see section [5] [vi] for a suggested regime).
- Have an IV line set up and running. Dilute the antivenom about 1:10 (1:5 or less may be needed if volume is a problem, i.e. polyvalent antivenom, paediatric patient), in IV fluid (e.g. normal saline, or Hartmans). Start infusion very slowly carefully observing patient for reaction (look for rash, particularly on body, hypotension, bronchospasm; in children warning signs also include nasal, palatal, or ocular pruritis, coughing, sneezing, profuse sweating, faecal or urinary urgency or incontinence, abdominal pain, and a sense of impending doom), and increase rate aiming to give whole dose over 15 to 20 minutes.

[iv] **Antivenom (AV) dose:**

- For some antivenoms, the manufacturer lists a recommended initial dose as one vial, but significant envenoming by some species may require more than

one vial. AV is only recommended if the patient is envenomed and the following recommended minimum starting doses for each AV are for patients showing systemic envenoming.

- Recommended minimum starting dose for **brown snake bite** is 2 vials of Seqirus Brown Snake AV.
- Recommended minimum starting dose for **tiger snake bite** is 2 vials of Seqirus Tiger Snake AV. A higher initial dose may be required for bites by giant races of tiger snake.
- Recommended minimum starting dose for **taipan bite** is 1 vial of Seqirus Polyvalent or Taipan AV, but in moderate to severe cases, or where the snake is known to be large or likely to produce more venom (ie some commercial captive specimens used for venom extraction) consider a higher initial dose.
- Recommended minimum starting dose for **mulga snake bite or Collett's snake bite** is 1 vial of Seqirus Black Snake AV.
- Recommended minimum starting dose for **red bellied black snake** or **blue bellied black snake** bite is 1 vial of Seqirus Tiger Snake AV OR 1 vial of Seqirus Black Snake AV (in general Tiger Snake AV is preferred).
- Recommended minimum starting dose for **death adder bite** is 1 vial of Seqirus Death Adder AV, but in severe cases consider a higher initial dose.
- One vial of Seqirus Polyvalent Snake AV is equivalent to 1 vial of relevant monovalent AV, as above.
- **Children require the same dose as adults.**
- Multiple bites or severe envenoming may require higher doses; increase the dose by 1-2 vials, depending on the clinical presentation and type of antivenom, and be prepared to give more. However, repeat doses of AV are not usually required, so seek expert advice (Clinical Toxinology Service at WCH; 8161 7000 & ask for duty clinical toxicologist).
- If there is a coagulopathy do not expect improvement in under 6 hrs and seek expert advice (see Section [8] for guide-lines on managing coagulopathy).

[vi] **Management of anaphylaxis reaction to antivenom:**

(i) *Preparation prior to commencing antivenom.*

1. Dedicate one small bore (18-20 G in adults) IV line to antivenom administration, and one large bore IV line (16-14 G in adults) for emergency resuscitation.
2. Prepare 1L Normal Saline (20 ml/kg in children) ready to give under pressure.
3. Prepare adrenaline 1:1000 (1mg in 1 mL) drawn up to a dose of 0.01 mg/kg (max. 0.3 mg, i.e. max 0.3 mL) and label "adrenaline for i.m. injection only (dose in mg)".
4. Consider preparing an i.v. infusion of adrenaline 1mg in 100 mL (controlled by infusion pump or syringe driver) ready to attach by a side arm to the resuscitation line, notably for patients with known pre-existing allergy to AV. Anti-reflux valves must be attached above the side arm on any other infusions using this i.v., to prevent adrenaline going back up into the other fluid bags. To prevent erroneous administration, do not attach the adrenaline infusion until needed.
5. Record blood pressures on the other side to the fluid/adrenaline infusion, to avoid pronged cuff inflations and thus extravasation of infusion fluids.

(ii) Management of a reaction

If there is anaphylaxis follow standard Advanced Life Support (ALS) Protocols for management of an anaphylactic reaction. Adverse reactions to antivenom, which may be independent of the rate of antivenom infusion, may present as flushing, hypotension and/or bronchospasm. Some mild reactions resolve with temporary cessation of the antivenom infusion and recommencing it at a slower rate. *Envenomed patients may be severely coagulopathic*, so it is important to be cautious when giving adrenaline to avoid blood pressure surges, which might lead to intracerebral haemorrhage.

If you do not have access to an ALS Protocol then do the following:

Initial management of severe reactions (hypotension, bronchospasm):

- Suspend the antivenom infusion.
- Lie the patient flat (if not already), commence high flow/100% oxygen and support airway/ventilation as required
- Rapid infusion of 1L N Saline (20 mL/kg in children) over 2-3 minutes
- Adrenaline IM into the lateral thigh, 0.01 mg/kg to maximum of 0.3 mg (alternatively, those experienced with i.v. adrenaline infusions may proceed directly to this, as below)
- Liaise with toxicology service regarding ongoing envenoming management

For reactions that do not respond to initial management:

- If hypotensive, repeat Normal Saline bolus as above (up to 50 mL/kg may be required)
- Commence i.v. infusion of adrenaline (0.5 mL/kg/hour, of 1 mg in 100 mL) and titrate according to response; monitor BP every 3-5 minutes (using the arm opposite to the infusion); beware that as the reaction resolves adrenaline requirements will fall, the blood pressure will rise and the infusion rate will need to be reduced
- Consider nebulised salbutamol for bronchospasm, nebulised adrenaline for upper airway obstruction, and i.v. atropine for severe bradycardia
- Seek advice urgently from the local/regional ED Consultant &/or ICU Consultant

[6] The patient appears well, no apparent evidence of envenoming.

[i] Quickly ascertain: History:

- was a snake seen to bite (?multiple bites) OR were the circumstances such that a bite might have occurred?
- when did the patient get bitten (elapsed time)?
- description of snake if possible (colour, length, mobile phone photo)
- geographic place that the incident occurred (snakes in area)
- timing and type of first aid and activity after the bite
- determine if there has been any evidence of envenoming; specifically ask about headache, nausea, vomiting, abdominal pain, blurred or double vision, slurring of speech, muscle weakness, respiratory distress, bleeding from the bite site or elsewhere, passing dark or red urine, local pain or swelling at the bite site, pain in lymph nodes draining the bite area (axilla, or groin), loss of consciousness, convulsions.
- relevant past history; specifically ask about allergy or past exposure to

antivenom, atopic history, renal, cardiac, or respiratory disease.

Examination: - assess patient status looking for:

- evidence of a bite (if there is an adequate first aid bandage in place, cut it away from over the bite site, keeping bandage from area adjacent to skin, DO NOT WASH WOUND, but consider swabbing for venom detection; see Section [4] (page 25) for technique of venom detection), look for evidence of multiple bites, or venom movement (swollen or tender draining lymph nodes),
- neurotoxic paralysis (ptosis or drooping eyelids, diplopia or double vision, fixed dilated pupils, dysarthria or slurred speech, drooling, limb weakness, decreased or absent deep tendon reflexes, respiratory distress),
- coagulopathy (bleeding from bite site, gums, or elsewhere),
- muscle damage (muscle tenderness, pain on movement, weakness, dark urine).

Investigations:

- complete blood picture (CBP/FBE/FBC)
- coagulation studies (PT/INR, aPTT, Fibrinogen, d-dimer/XDP/FDP)
- electrolytes (especially K⁺⁺), renal function, CK (for myolysis)
- IF no laboratory testing immediately available then perform a 20 minute whole blood clotting test (20WBCT) in a clean glass tube (see page 15)

[ii] If after performing the above there is evidence of envenoming then proceed as for Section [3] above (page 23).

[iii] If after performing the above there is no clinical evidence of envenoming then the patient will still need admission to hospital for observation overnight, preferably to a high intensity nursing area, ensuring that nursing staff are instructed to regularly check for signs of developing envenoming, especially early signs of paralysis (e.g. ptosis, diplopia etc). If there is clear evidence of a snakebite (e.g. bite site) then insert an IV line (normal saline, run at maintenance, fast patient for first 6-8 hours post bite). Monitor urine output and colour, check for blood. Ensure that the duty doctor will be notified of any changes immediately, and will then personally reassess the patient.

NOTE: There is no point in leaving first aid in place if the patient is well and in hospital and the hospital is able to treat snakebite (i.e. has the appropriate antivenom available). The first aid bandage and splint merely delays venom absorption, it does not inactivate venom, and delay in removing first aid will delay onset of definitive treatment of snakebite.

[7] Management of the severely ill patient, where diagnosis of snakebite is obscure:

[i] If the patient presents with unexplained onset of collapse, cardiac arrest, convulsions, bleeding, paralysis, rhabdomyolysis (e.g. muscle breakdown, myoglobinuria), or renal failure, in a setting where snakebite might have occurred (e.g. in rural areas, or gardens, paddocks, long grass in urban areas), and particularly in children who may give no history of exposure to snakes, then include snakebite in the differential diagnosis.

[ii] Useful tests to establish if there has been a snakebite include:

- Examine patient on exposed areas for bite marks or scratches.
 - coagulation studies (or 20WBCT if lab tests unavailable on site) to establish if there is a coagulopathy. (refer Section [8] for details of snakebite coagulopathy).
 - check for myolysis; dark or red urine indicative of myoglobinuria (positive for “blood” and so may be mistaken for haematuria), elevated CK (>1,500).
 - consider testing for venom in urine using SVDK (see Section [4]; page 25), but be aware of the potential for false positive results, particularly for brown snake venom.
 - if in doubt discuss with Clinical Toxinologist at WCH; 8161 7000.
- [ii] If there is clear evidence that a snakebite is the cause of the patient’s illness following the above, then **GO TO Section [3]** (page 23).
- If there is equivocal evidence of snakebite, seek advice as above.

[8] Snakebite Coagulopathy - Defibrination

- [i] Some snakes may cause a significant coagulopathy as part of envenoming (e.g. brown snakes, tiger snakes, rough scaled snakes, broad-headed snakes, Stephen’s banded snakes, taipans). This is due to potent procoagulants in the venom, which *in vivo* cause consumption of fibrinogen and fibrinolysis; the **DEFIBRATION SYNDROME** (also known as “VICC”). This may occur rapidly after onset of envenoming, and renders the blood UNCLOTTABLE, sometimes within 30 to 60 minutes of the bite. Platelets are usually unaffected, at least initially. Snakebite coagulopathy can prove complex to manage; it is preferable to treat the patient in a major hospital, with full coagulation laboratory facilities on site.
- [ii] **Tests for coagulopathy:**
- ***If there is no laboratory in your hospital***, perform a 20WBCT (see page 15 for details on method). Performing a 20WBCT is not a substitute for laboratory coagulation tests. Ideally it should be used as initial assessment prior to transfer to a hospital with laboratory facilities.
 - At the same time take blood for later laboratory tests; most useful tests are; prothrombin ratio (INR), aPTT, fibrinogen level, and fibrin(ogen) degradation products (XDP/d-dimer or FDP). In some laboratories a thrombin clotting time (TCT) may be useful to assess fibrinogen level. A complete blood picture (CBP/FBE) should be performed for platelet count.
 - In most cases a single batch of tests will not be sufficient, and serial studies will be needed.
- [iii] **Expected results in coagulopathy:**
- The 20WBCT will be positive (no clot at 20 mins., or there may be only a weak clot in less severe cases {normal= less than 10 mins.}).
 - INR (prothrombin time) grossly prolonged (>2, often infinity/>10). {normal= 1.0 }
 - aPTT grossly prolonged (>150 secs). {normal= less than 40 secs}
 - Thrombin clotting time (TCT) grossly prolonged (>150 secs). {normal 15 secs}
 - NOTE: TCT may be the first parameter to show improvement as a result of antivenom therapy, dropping from >150 secs to less than 100 secs. If this occurs it probably indicates that enough antivenom has been given, despite the lack of improvement in other parameters, and so at this stage cease further antivenom therapy and repeat tests in 1 hour to confirm trend of improvement.

- **Fibrinogen level very low** (<0.1 g/l). {normal= 1.5 to 4.0 g/l}. This is the key diagnostic finding in defibrination coagulopathy.
- Fibrin(ogen) degradation products grossly elevated (XDP/d-dimer > 16). {normal D-dimer=<0.5}. This is another key diagnostic finding. NOTE: Degradation products are in themselves anticoagulant, and at such high levels may interfere with some clotting tests, giving falsely high levels of abnormality, particularly INR and aPTT on some automated coagulation machines. This may obscure the first signs of recovery.
- ROTEM: This technology is currently available in only a few major hospitals and is still being evaluated for relevance in snakebite. Initial experience indicates while it may detect coagulopathy, it may not be as sensitive in detecting early developing defibrination as measuring the circulating D-dimer level and, for snakebite, may lack sensitivity and specificity.

[iv] **Management principles:**

- If initial studies are normal, remove PBI first aid and repeat studies after 1 hour, or sooner if the patient appears envenomed. If the second set of tests are also normal, repeat at 6 hrs and 12 hrs post-bite.
- If there is a significant coagulopathy (unclottable blood, or INR>2 + low fibrinogen), then this must be treated. Antivenom is the treatment of choice. Once active venom is all neutralised by antivenom normal homeostasis rapidly (sometimes within 3 hours, normally within 6-8 hrs) rectifies the problem, placing the patient out of danger (i.e. INR <4), usually without need of any other treatment. Replacement therapy with clotting factors (e.g. whole blood, FFP, cryoprecipitate) should be used only with great caution as it is liable to make the coagulopathy worse if there is still active venom present. Therefore routine use of replacement therapy is not appropriate. It should be reserved for only those patients with active major and potentially life threatening bleeding and then only after an adequate dose of AV has been given. In this latter setting consider giving a higher than normal dose of AV to ensure all circulating venom is neutralised, including late venom entering the circulation. One study showed that giving replacement therapy within 6 hrs of a bite was associated with a worse outcome, and giving it later than 6 hrs was not associated with an improved outcome, compared to patients not receiving this treatment.
- Titration of antivenom dose against the resolution of the coagulopathy is no longer recommended. If still showing a non-resolving coagulopathy at 6-8 hours (ie. no significant rise in fibrinogen level), with evidence of active bleeding (from IV sites, gums etc) consider giving more antivenom. Expert advice should be sought in all such cases (SA Clinical Toxinology Service; WCH 8161 7000).
- NOTE that even if enough antivenom has been given, some coagulation parameters will remain abnormal for many hours, especially fibrin(ogen) degradation products, which may remain elevated for 48hrs, longer if there is renal failure.

A rise in fibrinogen level from zero to detectable is the key indicator of resolution of the defibrination coagulopathy, not a return to normal fibrinogen levels, which may take many hours. In some laboratories, the first evidence of such a rise may be a fall in the aPTT or INR, rather than a change in detectable fibrinogen titres.

[9] Snakebite Coagulopathy - Anticoagulation

- This occurs after some severe bites by mulga snakes, Collett's snakes, spotted/blue bellied black snakes and red bellied black snakes and is due to direct anticoagulants in the venom, which interfere with clotting pathways. A similar effect has occasionally been observed following death adder bites, notably in New Guinea rather than Australia.
- This can result in a prolonged clotting time, elevated INR and aPTT, but fibrinogen levels and fibrin(ogen) degradation products are within the normal range. The anticoagulant effect generally affects the aPTT, with mild to moderate increase in the time. Rarely the INR may be grossly elevated, exceptionally >12. However, without a full clotting laboratory, this may be hard to ascertain, and the 20WBCt might be prolonged in these patients, though a clot should eventually form, unlike defibrination coagulopathy, as discussed earlier.
- Experience has shown that persistent ooze from the bite site or elsewhere is not likely as a result of venom induced direct anticoagulation, again, different to defibrination coagulopathy. Brown snakes, tiger snakes, taipans and other species causing defibrination do not cause this direct anticoagulation, as discussed earlier.
- Antivenom is very effective at rapidly reversing direct anticoagulation coagulopathy. Usually one vial of antivenom will suffice.

[10] Snakebite Myolysis

- This occurs most commonly after bites by tiger snakes, rough-scaled snakes and members of the black snake genus (mulga snakes/king browns, Collett's snake, black snakes), but may also occur occasionally after taipan bites. Mulga snakes can cause severe rhabdomyolysis (CK sometimes >100,000IU/l) while bites by red-bellied black snakes and spotted/blue-bellied black snakes generally result in low level myolysis (CK 500-3,000IU/l), though occasionally can cause moderate myolysis (CK 10-20,000IU/l).
- Snakebite rhabdomyolysis is the result of widespread direct damage to striated muscle cells, resulting in complete muscle cell breakdown within 1-3 days, though damage probably commences within 1-3 hrs of venom reaching the muscle. Full recovery is possible, but may take 4+ weeks.
- The key diagnostic indicators are myoglobinuria (easily mistaken for haematuria) and a dramatic rise in plasma CK. The latter may reach figures much greater than 100,000IU/l, but may take 48 hrs to do so, with minimal rises present in the first 6-12 hrs. This latter delay is important to consider in assessing if and when a snakebite patient may be safe to discharge. In addition, patients complain of generalised muscle pain, with tender muscles. In severe cases there may be extensive muscle wasting.
- The secondary effects of myolysis are renal failure and massive hyperkalaemia, which can be very difficult to control and has proven lethal due to cardiac toxicity.
- Once myolysis is established it is uncertain if antivenom will reverse damage, but in severe cases it may be worth trying further large doses of specific antivenom. In black snake bites, very early use of AV has been associated with a reduced incidence of rhabdomyolysis, but it currently remains unclear if this is

a coincidental finding, or actually represents a muscle-protective effect of early AV therapy. Because most bites by black snakes are not severe, the use of early AV as a routine in all such bites remains unproven and is not currently recommended. However, a more proactive use of early antivenom for mulga snake bites may have merit, but is not a current recommendation.

- The value of alkalinisation of urine in cases of snakebite rhabdomyolysis is unproven and not currently recommended.

[11] Snakebite Neurotoxic Paralysis

- Presynaptic neurotoxic flaccid paralysis may occur after bites by tiger snakes, rough-scaled snakes, copperheads, taipans, rarely brown snakes.
- It usually first manifests as ptosis, 1-3+ hours after the bite, with potential progression to partial ophthalmoplegia, complete ophthalmoplegia, fixed dilated pupils, dysarthria, dysphagia, peripheral weakness, decreased or absent deep tendon reflexes, culminating in respiratory paralysis, though it may take 24+ hours to reach this final stage.
- Loss of upper airway protection may force early intubation, well before full respiratory paralysis is established.
- Once complete paralysis is established it may take days, weeks or longer to reverse sufficiently for the patient to survive off a ventilator.
- Antivenom will not reverse well established presynaptic paralysis.
- Pure postsynaptic neurotoxic flaccid paralysis may occur after bites by death adders, resulting in similar, but often more rapid progression of symptoms and signs. This form of paralysis is usually reversible if sufficient antivenom is given. Neostigmine may also reduce the degree of paralysis, by making more neurotransmitter available at the neuromuscular junction, partially overcoming the postsynaptic block. Note that some death adders have dominant presynaptic neurotoxins, so may fail to respond to either AV, or neostigmine.
- If dominant postsynaptic neurotoxic paralysis is suspected, such as in death adder bites, then a trial of anticholinesterases may be considered (the Tensilon test using a short acting anticholinesterase) and if positive (a reduction in paralytic features), then a longer acting anticholinesterase may be considered, such as neostigmine, plus atropine. However, anticholinesterase treatment is only an adjunct to AV, and should never be used instead of AV.

[12] Followup of Snakebite Patients

- All patients with systemic envenoming should be followed up with particular concern for serum sickness over the first 14 days. Consider giving a 7 day course of oral steroids as prophylaxis if more than 25mls of antivenom has been given.
- As with all injuries causing skin penetration, ensure the patient has adequate **tetanus immune status** before discharge, irrespective of whether they were envenomed, or not. CAUTION: Do not give an IM tetanus booster injection until it is clear that the patient does not have, or no longer has an active coagulopathy. An IM injection in the presence of active coagulopathy can cause significant intramuscular bleeding and trauma.
- It is important to follow up all patients with initially trivial or no apparent enven-

oming, especially if discharged less than 24hrs post-bite, to ensure late onset envenoming is not missed. In particular, look for late onset neurotoxic envenoming, myolysis (not if proven brown snake bite) and renal damage.

PROTOCOL FOR MANAGING A CASE OF SNAKEBITE IN A HOSPITAL WITHOUT ANTIVENOM AVAILABLE

[1] The patient presents with a definite or possible snakebite.

- If not already applied, immediately apply correct first aid, namely a *broad compressive bandage* (PBI) bound first over the bite site, at the *same pressure as for a sprain* (i.e. not so tight that it occludes the blood supply), then bind the bandage over as much of the bitten limb as possible, going over the top of clothing, and keeping the limb as still as possible. Once the limb is bandaged, *immobilise it using a splint*.
- Do NOT wash the wound, but if a venom detection kit is available then swab the wound as directed (see page 25 for details on SVDK) prior to applying first aid, but do not delay first aid significantly just to swab for venom, unless the patient appears well and greater than 20mins has elapsed since the bite.
- Keep the patient as still and quiet as possible.
- Insert an IV line and give an initial fluid load IV. Do not allow the patient to run dry as this may increase the chance of secondary renal injury.
- Fast the patient (for 4-8 hrs post-bite), and be prepared for vomiting.
- Carefully watch for evidence of envenoming, and if there is respiratory embarrassment, give respiratory support.
- Monitor urine output and colour.
- If the snake was brought with the patient, place it in alcohol (if practical), and ensure it goes with the patient when retrieval occurs.

[2] As soon as possible after applying first aid as above, notify the relevant doctor or hospital, to organise medical retrieval. In SA this will involve MED-STAR.

- It will help the retrieval team if you can give the following patient status report:
- Name, sex, age of patient.
- Brief history of the suspected bite. Was a snake seen? What type of snake? Was it a multiple bite? Are there any symptoms or signs of envenoming? (namely; headache, nausea, vomiting, abdominal pain, collapse, convulsions, early paralysis such as drooping upper eyelids, double vision, slurred speech, limb weakness, evidence of bleeding problem such as persistent ooze from the bite site, evidence of muscle damage such as dark or red urine, muscle pain).
- Patient's past history, particularly past snakebites with antivenom therapy, allergic disease, renal or heart disease, or use of anticoagulant drugs (e.g. warfarin) or antiplatelet drugs (e.g. aspirin or NSAIDS).

COMPARING HEAD SCALATION AND APPEARANCE TO DETERMINE THE MOST LIKELY TYPE OF SNAKE

Head shape and scalation can be very useful in determining the type of snake. When a dead snake, with head intact, is brought in with the patient, examination of the head should be performed. Once used to looking at the heads of the three major dangerous snakes in SA it is often possible to distinguish between them. The Photos shown here are of reasonably typical specimens.

The shape of the head; is it broad and triangular (eg mulga snake), broad and square (eg tiger snake), or narrow with brow ridges (eg brown snake) is of particular relevance. Refer to the diagram on page 39 and the colour key on page 38 for matching scale names to individual scales.

If you consult a clinical toxinologist for assistance they will ask you about the head appearance. If you are able to take digital photos and send them (eg by email or mobile phone), then close ups of the head from above and the side will be most useful.



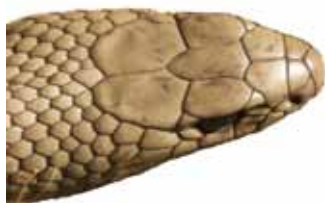MULGA SNAKE (*Pseudechis australis*)

The head is broad and triangular. The parietal scales are triangular and at their neck edge, there are several rows of smaller scales visible, before the side of the head is reached.



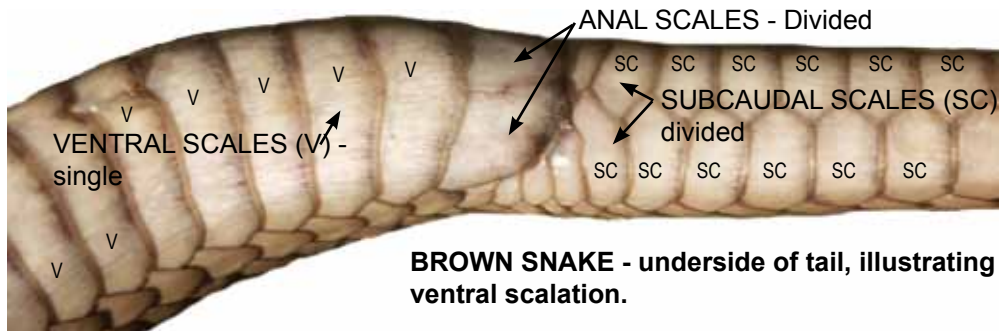
TIGER SNAKE (*Notechis scutatus/ater*)

The head is broad and more square in shape. The parietal scales are less triangular and broader, with fewer rows of scales leading to the side of the head and these scales are larger in proportion to the parietals, than in the mulga snake.



BROWN SNAKE (*Pseudonaja textilis/aspidorhynca*)

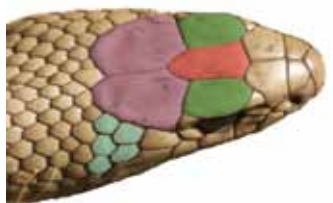The head is more narrow and elongated than in either the tiger snake or mulga snake. There is a prominent scale ridge, or brow, above the eye, noticeably different to the mulga snake. The parietals are triangular, but less acutely so than the mulga snake. The frontal scale is much more elongate than either the mulga snake or tiger snake.



BROWN SNAKE - underside of tail, illustrating ventral scalation.

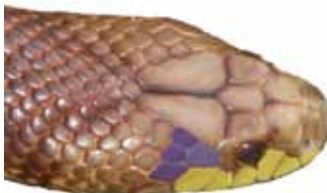- Parietal scales
- Frontal scale
- Supraocular scales
- "side scales" to rear of head

Patterns based on head shape and parietal and frontal scales.



- Temporal scale
- Post-temporal scales
- Supralabial scales

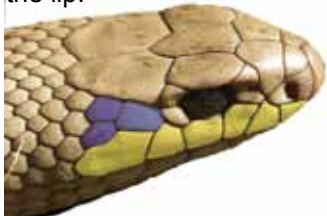Classic taxonomic differentiation using temporal and post temporal scales.



MULGA SNAKE - temporal scale + 3 post temporal scales. Note scale below touches lip and is therefore a supralabial scale.



TIGER SNAKE - temporal + 2 post temporal scales. Note scale below does not fully touch the lip.

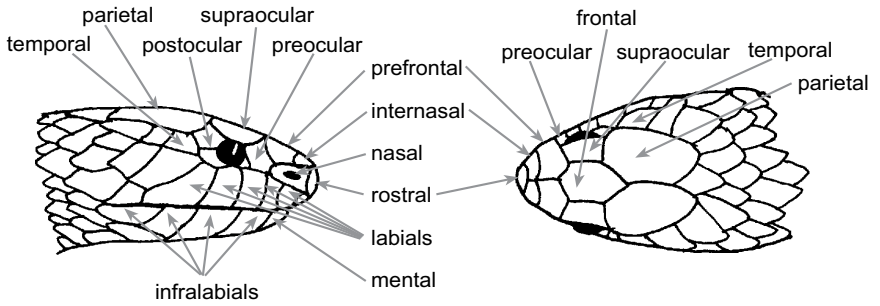


BROWN SNAKE - temporal + 2 post temporal scales. Note scale below touches lip and is therefore a supralabial scale.

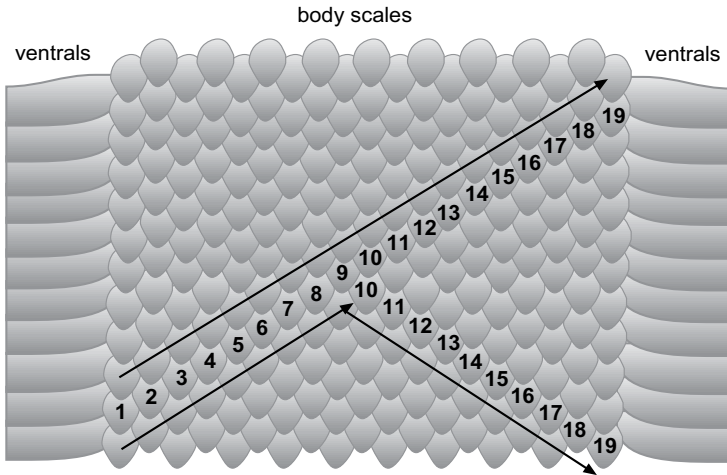
DETAILS OF MAJOR VENOMOUS SNAKES

DETAILS OF SCALE NAMES AND COUNTS

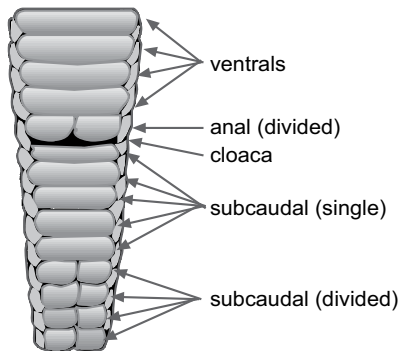
HEAD SCALATION OF AN ELAPID SNAKE



MIDBODY SCALE COUNT



VENTRAL, ANAL & SUBCAUDAL SCALES



SCALE COUNT DETAILS

Snake	Scientific name	MidBody	Ventral
Eastern brown snake	<i>Pseudonaja textilis</i>	17	185-235
Western brown snake	<i>Pseudonaja aspidorhyncha</i>	17	207-226
Gwardar	<i>Pseudonaja mengdeni</i>	17	193-224
Dugite	<i>Pseudonaja affinis</i>	19	190-230
Peninsular brown snake	<i>Pseudonaja inframacula</i>	17	190-205
Speckled brown snake	<i>Pseudonaja guttata</i>	19-21	190-220
Ringed brown snake	<i>Pseudonaja modesta</i>	17	145-175
Tiger snake	<i>Notechis scutatus</i>	19	140-190
Mulga snake	<i>Pseudechis australis</i>	17	185-225
Collett's snake	<i>Pseudechis colletti</i>	19	215-235
Red bellied black snake	<i>Pseudechis porphyriacus</i>	17	170-215
Blue bellied black snake	<i>Pseudechis guttatus</i>	19	175-205
Inland taipan	<i>Oxyuranus microlepidotus</i>	23	220-250
Common death adder	<i>Acanthophis antarcticus</i>	21	110-135
Desert death adder	<i>Acanthophis pyrrhus</i>	19-21	120-160
Yellow faced whip snake	<i>Demansia psammophis</i>	15	165-230
White lipped snake	<i>Drysdalia coronoides</i>	15	120-160
Masters's snake	<i>Drysdalia mastersii</i>	15	134-160
Bardick	<i>Echiopsis curta</i>	19	130-145
Red naped snake	<i>Furina diadema</i>	15	160-210
Orange naped snake	<i>Furina ornata</i>	15-17	160-240
Northern desert banded snake	<i>Simoselaps anomalus</i>	15	115-130
Coral snake	<i>Brachyuropsis australis</i>	17	140-170
Desert banded snake	<i>Simoselaps bertholdi</i>	15	110-135
Western black-naped snake	<i>Neelaps bimaculatus</i>	15	175-235
Narrow banded snake	<i>Brachyuropsis fasciolatus</i>	17	140-175
Half girdled snake	<i>Brachyuropsis semifasciatus</i>	15-17	140-190
Little whip snake	<i>Parasuta flagellum</i>	17	125-150
Hooded snake	<i>Parasuta monachus</i>	15	150-175
Mallee black-headed snake	<i>Parasuta nigriceps</i>	15	145-175
Black headed snake	<i>Parasuta spectabilis</i>	15	135-170
Curl snake	<i>Suta suta</i>	19-21	150-170
Bandy bandy	<i>Vermicella annulata</i>	15	180-320
NON-VENOMOUS			
Pythons (various species)		>35	-
Blind snakes	<i>Ramphotyphlops</i> species	Very distinctive head, body (see photos)	

SCALE COUNT DETAILS

Snake	Anal	Subcaudals	Adult length
Eastern brown snake	divided	45-75; divided	1.5m
Western brown snake	divided	47-63; divided	1.5m
Gwardar	divided	49-64; divided	1.3m
Dugite	divided	50-70; divided	1.2m
Peninsular brown snake	divided	52-62; divided	1.1m
Speckled brown snake	divided	45-70; divided	0.8m
Ringed brown snake	divided	35-55; divided	0.5m
Tiger snake	single	35-65; single	1.2m
Mulga snake	divided	50-75; first few single	2.3m
Collett's snake	divided	50-70; first few single	2.0m
Red bellied black snake	divided	40-65; single to divided	1.4m
Blue bellied black snake	divided	45-65; first few single	1.5m
Inland taipan	single	55-70; divided	2.5m
Common death adder	single	35-60; mostly single	0.5m
Desert death adder	single	40-65; first few single	0.5m
Yellow faced whip snake	divided	60-105; divided	1.0m
White lipped snake	single	35-70; single	0.3m
Masters's snake	single	32-55; single	0.25m
Bardick	single	30-40; single	0.4m
Red naped snake	divided	35-70; divided	0.4m
Orange naped snake	divided	35-70; divided	0.7m
Northern desert banded snake	divided	15-30; divided	0.2m
Coral snake	divided	15-30; divided	0.3m
Desert banded snake	divided	15-30; divided	0.3m
Western black-naped snake	divided	15-35; divided	0.3m
Narrow banded snake	divided	15-30; divided	0.3m
Half girdled snake	divided	14-30; divided	0.3m
Little whip snake	single	20-40; single	0.3m
Hooded snake	single	20-35; single	0.4m
Mallee black-headed snake	single	18-35; single	0.4m
Black headed snake	single	20-40; single	0.4m
Curl snake	single	20-35; single	0.5m
Bandy bandy	divided	12-30; divided	0.6m
NON-VENOMOUS			
Pythons (various species)	-	-	-

BROWN SNAKES

Genus *Pseudonaja*

[1] EPIDEMIOLOGY

Brown snakes cause the majority of snakebites in Australia. However because of the small amount of venom available (average only 5 mg.) and the small fang size (average length only 2.8 mm.), many bites do not result in significant envenoming. On average only 1 in 5 or less brown snake bites is severe enough to require antivenom therapy. Nevertheless, when a significant amount of venom is injected, it can cause major and life threatening envenoming very rapidly. All brown snake bites should be treated as potentially lethal.

[2] TAXONOMY

Snake	Scientific name	Mid body scale count	Ventral scale count	Anal scale count	Subcaudal scale count
Common brown snake	<i>P. textilis</i>	17 rows	185-235	divided	45-75
Western brown snake	<i>P. aspidorhyncha</i>	17-19 rows	207-226	divided	47-63
Gwardar	<i>P. mengdeni</i>	17 rows	193-24	divided	49-64
Ringed brown snake	<i>P. modesta</i>	17 rows	145-175	divided	35-55
Peninsular brown snake	<i>P. inframacula</i>	17 rows	190-205	divided	52-62
Spotted brown snake	<i>P. guttata</i>	19 rows	190-220	divided	45-70
Dugite	<i>P. affinis</i>	19 rows	190-230	divided	50-70

The ringed brown snake is smaller than its cousins, and although it can cause envenoming, there is no evidence that it can cause severe or life threatening envenoming, and unlike all its cousins, the venom lacks a procoagulant and therefore cannot cause a coagulopathy.

The colour of brown snakes is very variable and misleading for identification purposes. They may be brown, red brown, grey, very dark brown and may be plain in colour, have speckling, stripes or bands, or have a dark or black head. Length is variable, but can occasionally reach 2m.

[3] DISTRIBUTION

Widely distributed throughout Australia including both arid areas and wetter areas. Adapt well to human land use and are the most common snake in urban areas and farmlands. The maps show approximate theoretical distribution only.

[4] CLINICAL VENOM EFFECTS


Powerfully toxic venom, with potential to cause coagulopathy, renal failure and paralysis. In practice the dominant feature of brown snake envenoming is coagulopathy (defibrination type). Paralysis is only very rarely seen, usually in bites where there has been a long delay in giving antivenom therapy. Renal failure is a



The common brown snake - *Pseudonaja textilis* and it's approximate distribution in SA. The right hand specimen is a juvenile showing the classic black markings on top of the head and black band on the neck.



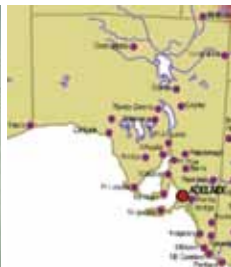The western brown snake - *Pseudonaja aspidorhyncha* and the Gwardar, *P. mengdeni*, approximate distribution in SA. Note the varied colour patterns present within these species, including black headed varieties.



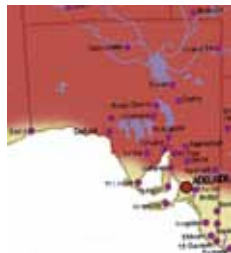The peninsular brown snake - *Pseudonaja inframacula* and it's approximate distribution in SA.



The dugite - *Pseudonaja affinis* and it's approximate distribution in SA.



The spotted brown snake - *Pseudonaja guttata* and its approximate distribution in SA (just in the far north east corner).



The ringed brown snake - *Pseudonaja modesta* and its approximate distribution in SA. Note the 5 pale rings located at intervals along the body.

moderately common feature of brown snake envenoming in adults and is usually an acute tubular necrosis, which may require a period of haemodialysis. The risk seems increased if the patient has also had alcohol near the time of the bite. If renal failure is present then the coagulopathy is usually of the true DIC type, with thrombocytopenia.

The ringed brown snake does not appear to cause coagulopathy or severe envenoming.

[5] ANTIVENOM

Preferred antivenom is Seqirus Brown Snake Antivenom. If there is a coagulopathy, expect to use 2 vials, rarely more. The initial dose if there is defibrination coagulopathy is 2½ vials.

[6] VENOM DETECTION

The expected pattern if brown snake venom is present is positive in well 2 + well 7 (positive control). It is unclear what pattern may result with ringed brown snake venom.

§ An ongoing prospective study of Australian snakebite (ASP Study) has generated information that has been interpreted by the principals as indicating only 1 vial of AV is ever required for any Australian snakebite. The consultant clinical toxinologists in the SA Clinical Toxinology Service dispute this interpretation and recommendation, hence the advice to use 2 vials of brown snake AV in these guidelines, while for other snake antivenoms, depending on clinical setting, a single vial may be initially appropriate.

TIGER SNAKES

Genus *Notechis*

[1] EPIDEMIOLOGY

Tiger snakes are the second most important cause of snake bites and fatalities. In general they are wetlands snakes, with a more restricted distribution, usually in association with creeks and rivers or water storage areas and lakes. Historically, untreated tiger snake bites have resulted in nearly 50% mortality and they are much more likely to inflict a severe bite than brown snakes. They have small fangs (average length 3.5mm) and produce a moderate amount of highly toxic venom (average 35mg.).

[2] TAXONOMY

There is only one species, the common tiger snake *Notechis scutatus*, with a number of melanistic subspecies or races, notably black tiger snakes *N. scutatus ater*, *N.s.niger* etc several of which occur in SA. They have body scales in 17-19 rows, with 140-190 ventral scales, a single (undivided) anal scale and 35-65 undivided subcaudal scales and may reach 1.2 metres in length.

[3] DISTRIBUTION

Largely restricted to wetter areas of south east SA and along the River Murray (*N. scutatus*), and on Kangaroo Island and isolated populations (*N. s. ater* & *N.s.niger*).

[4] CLINICAL VENOM EFFECTS

Powerfully toxic venom, with potential to cause defibrination type coagulopathy, paralysis, myolysis, and secondary renal failure. Coagulopathy may be severe with



Common banded form, and unbanded brown form of mainland tiger snake (*Notechis scutatus*).



Common black form and copper brown form (from Kangaroo Island) of black tiger snake (*Notechis scutatus ater*).

lethal haemorrhages reported, but untreated, tends to spontaneously resolve in about 12-18 hours. Paralysis is principally presynaptic and is common in moderate to severe cases of envenoming. Once full paralysis is established it will not usually be reversible with antivenom. Myolysis may be very severe, often with secondary renal failure and hyperkalaemia.

[5] ANTIVENOM

Preferred antivenom is Seqirus Tiger Snake Antivenom. One vial is rarely sufficient. If there is evidence of coagulopathy, paralysis or myolysis, initial dose should be 2 vials (rarely more), with further doses occasionally necessary.

[6] VENOM DETECTION

The expected pattern if tiger snake venom is present is positive in well 1 + well 7 (positive control), but in addition, occasionally there may be a weak positive in wells 3 and 4.

ROUGH SCALED SNAKE

Tropidechis carinatus

[1] EPIDEMIOLOGY

The rough scaled snake is similar in many ways to the tiger snake, frequenting mostly wetter areas. Though technically considerably less dangerous than the tiger snake, clinical experience has shown it to be almost identical in effects in humans and it should be considered lethal. Within its range it is probably causing bites more frequently than tiger snakes. Fang length and venom quantity is less than for tiger snakes.

[2] TAXONOMY

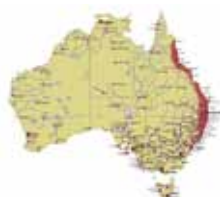There is a single species. It has strongly keeled body scales, 23 rows mid-body, 160-185 ventral scales, anal scale undivided, 50-60 undivided subcaudals. It may reach 1 metre in length. Colouration is variable, but most specimens have an overall olive colour above, with irregular darker cross bands, while the belly scales are mostly cream or yellow, sometimes with darker areas.

[3] DISTRIBUTION

Rough scaled snakes are mainly found near watercourses or in sclerophyl forests in eastern Australia. They are not native to SA.

[4] CLINICAL VENOM EFFECTS

Despite the major clinical effects of rough scaled snake bites, comparative testing shows the venom as much less toxic than tiger snake venom. Clinically, however, all the major problems seen with tiger snake bites occur; namely defibrination coagulopathy, presynaptic paralysis and major myolysis, with possible secondary renal failure.



[5] ANTIVENOM

The preferred antivenom is Seqirus Tiger Snake Antivenom. In cases with severe envenoming multiple vials may be needed, with a starting dose of at least 2 vials.

[6] VENOM DETECTION

The expected pattern if rough scaled snake venom is present is positive in well 1 + well 7 (positive control).

COPPERHEADS**Genus *Austrelaps*****[1] EPIDEMIOLOGY**

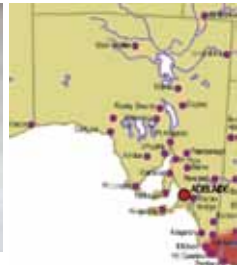Copperheads are also snakes that prefer wetter, cooler areas, right up into alpine regions. Though probably not rare, bites are rarely reported and there is comparatively little known about envenoming by these snakes. Based on venom and animal studies and a few case reports, bites are potentially lethal and likely to be similar to tiger snake bites. Fangs and venom quantities are also comparable, though venom toxicity is less.

[2] TAXONOMY

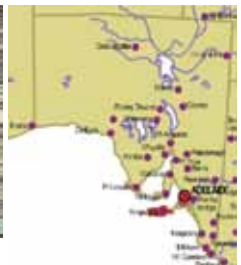Copperheads are restricted to south east Australia. Colouration is quite variable, often with russet tinge to upper surface, blending to yellow or cream on belly scales. As with other copperheads, they typically have pale or white markings on the edge of lip scales. Midbody scales in 15 rows, 150 ventrals, anal undivided, 35-55 undivided subcaudals, length to 1.2 metres.

[3] DISTRIBUTION

In SA all specimens are either lowland copperheads, *Austrelaps superbus* in the South East, or pygmy copperheads, *A. labialis* in the Mount Lofty Ranges and on Kangaroo Island.



Common or lowlands copperhead (*Austrelaps superbus*).



Pygmy copperhead (*Austrelaps labialis*).

[4] CLINICAL VENOM EFFECTS

The principal clinical effect of copperhead bites appears to be paralysis, while neither myolysis nor coagulopathy are well documented in humans envenomed by these snakes. Based on experimental work there may be myolysis, but coagulopathy, if present at all, seems more likely to be direct anticoagulant rather than defibrination.

[5] ANTIVENOM

Current recommendations are to use Seqirus Tiger Snake Antivenom, but dosage is uncertain. In severe cases, use at least 2 vials.

[6] VENOM DETECTION

Copperheads tested for venom detection have been principally *Austrelaps superbus*, not *A. labialis*. The expected pattern if copperhead venom is present is positive in well 1 + well 7 (positive control), but there may also be a weak positive in well 3.

BROAD HEADED SNAKES

Genus *Hoplocephalus*

[1] EPIDEMIOLOGY

The three members of this genus are the broad headed snake, *Hoplocephalus bungaroides*, Stephen's banded snake, *Hoplocephalus stephensii* and the pale headed snake, *Hoplocephalus bitorquatus*, none of which are frequent causes of envenoming. Most cases are in researchers or reptile keepers, but accidental cases doubtless occur occasionally in the general population living in the ranges of these snakes. Fangs are small, venom quantity equally small, but recent clinical experience suggests these snakes could cause lethal envenoming.

[2] TAXONOMY

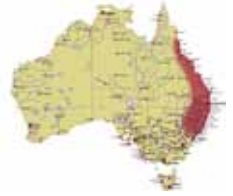All three species are small to medium sized thin snakes, with distinctive colouration for each species. The broad headed snake is typically black above with yellow scales forming irregular narrow bands, with a cream belly. There are 21 rows of midbody scales, 200-230 ventral scales, an undivided anal scale and 40-65 undivided subcaudals, with length to 0.9 metres. Stephen's banded snake is typically dark grey to almost black, with wide cross bands of a slightly lighter hue, often with pale or white markings around the lips or side of the head. Midbody scales in 21 rows, with 220-250 ventrals, an undivided anal scale, 50-70 undivided subcaudals and length to 0.6 metres. The pale headed snake is typically uniform grey or light brown in body colour, with a broad pale band on the nape of the neck, often bordered by narrow black markings. The top of the head is usually grey, sometimes with spots. Midbody scales in 21 rows, 190-225 ventrals, undivided anal scale, 40-65 undivided subcaudals, length to 0.6 metres.

[3] DISTRIBUTION

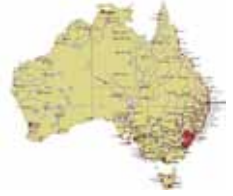None of these snakes are native to SA. The broad headed snake is restricted to ranges in south and central eastern NSW, where it favours sandstone rock areas, sheltering under rocks, venturing forth at night in search of prey. Stephen's banded snake is found in north eastern coastal NSW and adjacent Queensland and is



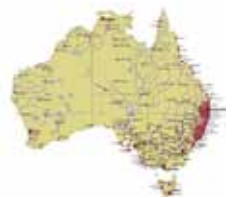Pale headed snake



Broad headed snake



Stephen's banded snake



nocturnal and partly arboreal. The pale headed snake is more broadly distributed in north eastern NSW and Queensland and is also nocturnal and partly arboreal in habit.

[4] CLINICAL VENOM EFFECTS

Few bites from any of these snakes are reported, but recent experience with bites by both the broad headed snake and Stephen's banded snake indicate that severe envenoming can occur in humans, with defibrination coagulopathy. Paralysis, myolysis and renal failure have not been reported so far. Though no deaths are reported, complete defibrination can potentially result in lethal haemorrhage, so these snakes are considered as possibly deadly.

[5] ANTIVENOM

While not formally tested, Seqirus Tiger Snake Antivenom has been used in several cases with apparent success. 2+ vials may be required to reverse the defibrination.

[6] VENOM DETECTION

Tests at Seqirus on Stephen's banded snake venom failed to show reactivity in the SVDK, but clinically it appears that at least the broad headed snake may give a weak positive in well 1 + well 7 (positive control). If in the range of these snakes, consider them as a cause of envenoming if the patient has defibrination without paralysis or myolysis, but the SVDK is negative or weakly positive for tiger snake venom.

MULGA SNAKES

Pseudechis australis

[1] EPIDEMIOLOGY

Mulga snakes are probably the second most common cause of significant snakebite in arid areas of Australia. Few cases are recorded in the medical literature, but they are known to cause fatalities and severe envenoming. While their venom is less potent than some other species (e.g. browns, tiger snakes, taipans), they produce large quantities (up to 180 mg.), and have quite large fangs (up to 6 mm.). The majority of mulga snake bites will result in significant envenoming, requiring antivenom therapy.

[2] TAXONOMY

The mulga snake, or king brown, *Pseudechis australis*, is a member of the black snake group, but far more dangerous than its cousins. It has 17 scale rows, 185-225 ventral scales, a divided anal scale, and 50-75 subcaudals, some or all of which may be divided. It is a large snake, usually brown in colour, with a slight yellow tinge to the edge of each scale, giving a distinctive appearance. The head is triangular, flattened, and broad.

[3] DISTRIBUTION

Widely distributed in the more arid parts of Australia, but generally less common than brown snakes. The map shows approximate theoretical distribution only.

[4] CLINICAL VENOM EFFECTS

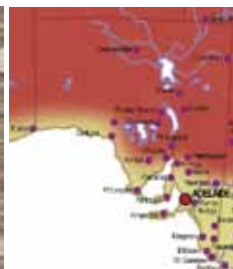Moderately powerful venom, principal effect being myolysis of skeletal muscle, with the potential for secondary renal failure and hyperkalaemia. True paralysis does not seem to occur with mulga snake bites, but the muscle damage may be severe enough to cause direct muscle weakness, which might mimic paralysis. The venom does not contain procoagulants, but rather direct anticoagulants. Defibrination coagulopathy is not seen, but there may be slight (occasionally marked) prolongation of clotting times, INR, APTT, due to the anticoagulants. Mulga snake bites are usually associated with significant local swelling and pain at the bite site. The swelling may take several hours to fully develop, but many days to fully subside.

[5] ANTIVENOM

Preferred antivenom is Seqirus Black Snake Antivenom. Usually one vial is sufficient. Bites by Collett's snake, *P. colletti*, should be treated as for mulga snakes.

[6] VENOM DETECTION

The expected pattern if mulga snake venom is present is positive in well 3 + well 7 (positive control), but there may also be weak positive in well 1.



RED BELLIED BLACK SNAKE

Pseudechis porphyriacus

[1] EPIDEMIOLOGY

Black snakes are found principally in wetter areas, typically near creeks. In eastern Australia they are common in areas frequented by man, and many bites have been recorded. It is clear that this snake is not particularly dangerous, and few fatalities are recorded. While its bite may often cause a local and even mild systemic reaction, potentially lethal bites are rare and therefore not every case with envenoming warrants antivenom therapy (seek expert advice on when to use AV).

[2] TAXONOMY

The black snake is of moderate size, usually over 1 metre in length, typically with a jet black body and an underside (ventral scales) which is deep red in colour, extending a short way up the sides of the snake. It has scales in 17 rows, with 180-210 ventral scales, a divided anal scale and 40-65 subcaudal scales, divided anteriorly.

[3] DISTRIBUTION

Wetlands snake, common near creeks and water. The map shows approximate theoretical distribution only and in much of this range it may be uncommon.

[4] CLINICAL VENOM EFFECTS

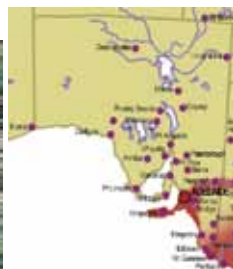The venom is neither particularly potent, nor in very large quantity. It does not appear to cause some of the major complications of Australian snake venoms; it does not cause paralysis, and usually only minor anticoagulant coagulopathy and myolysis, with renal failure rare in humans. However envenoming is associated with systemic symptoms, including headache, severe abdominal pain, nausea and vomiting, possibly syncope and the bite site is often painful and swollen and may become infected.

[5] ANTIVENOM

Not all envenomed cases require antivenom. If it is needed the preferred antivenom is Seqirus Tiger Snake Antivenom (rather than Black Snake Antivenom, though this may also be used). In reptile keepers, where there is a risk of repeated exposure to antivenom and the attendant possibility of developing hypersensitivity to antivenom, it is particularly important to avoid unnecessary exposure. Reptile keepers bitten by black snakes should be given antivenom therapy more cautiously.

[6] VENOM DETECTION

The expected result is positive in well 3 + well 7 (positive control), but there may also be a weak positive in well 1 (see mulga snake).



SPOTTED OR BLUE BELLED BLACK SNAKE

Pseudechis guttatus

[1] EPIDEMIOLOGY

Little is known about bites by this snake, but it is usually considered similar to the red bellied black snake, so bites are unlikely to prove lethal. However, the related Collett's snake has now caused severe envenoming, so that the clinical status of this snake is uncertain.

[2] TAXONOMY

The spotted or blue bellied black snake is of moderate size, usually over 1 m. in length, typically with a black or deep brown body, the latter usually with black or dark spots, and an underside (ventral scales) which is blue grey in colour, extending a short way up the sides of the snake. It has mid body scales in 19 rows, with 175-205 ventral scales, a divided anal scale and 45-65 subcaudal scales.

[3] DISTRIBUTION

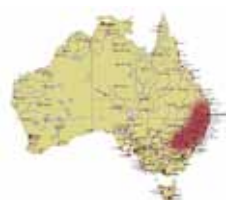Found in both dry and moist habitats in eastern Australia, not native to SA. The map shows approximate theoretical distribution only. There are verbal reports that this snake is increasingly common within parts of its range, at the expense of the red bellied black snake.

[4] CLINICAL VENOM EFFECTS

The venom is neither particularly potent, nor in very large quantity. It does not appear to cause some of the major complications of Australian snake venoms; it does not cause paralysis, and usually only minor anticoagulant coagulopathy and myolysis, with renal failure rare in humans. However envenoming, based on very limited case material, is associated with systemic symptoms, including headache, severe abdominal pain, nausea and vomiting, possibly syncope and the bite site is often painful and swollen and may become infected.

[5] ANTIVENOM

Not all envenomed cases require antivenom. If it is needed the preferred antivenom is Seqirus Tiger Snake Antivenom (rather than Black Snake Antivenom, though this may also be used). In reptile keepers, where there is a risk of repeated exposure to antivenom and the attendant possibility of developing hypersensitivity to antivenom, it is particularly important to avoid unnecessary exposure. Reptile keepers bitten by black snakes should be given antivenom therapy more cautiously.



[6] VENOM DETECTION

Expected result is positive in well 3 + well 7 (positive control), but there may also be a weak positive in well 1 (see mulga snake).

COLLETT'S SNAKE

Pseudechis colletti

[1] EPIDEMIOLOGY

Collett's snakes cause few bites, mostly in reptile keepers. They are known to cause severe envenoming, with the potential for lethality. While their venom is less potent than some other species (e.g. browns, tiger snakes, taipans), they produce large quantities, and have quite large fangs. The majority of Collett's snake bites will result in significant envenoming, requiring antivenom therapy. They should be considered similar to mulga snakes clinically.

[2] TAXONOMY

The Collett's snake, *Pseudechis colletti*, is a member of the black snake group, but far more dangerous than it's cousins, the red-bellied and blue-bellied black snakes. It has 19 scale rows, 215-235 ventral scales, a divided anal scale, and 50-70 subcaudals, some or all of which may be divided. It is a large snake, usually pink-brown in colour, with pinkish markings along the body, giving a distinctive appearance. The head is triangular, flattened, and broad.

[3] DISTRIBUTION

Restricted to parts of inland arid Queensland. Not native to SA. The map shows approximate theoretical distribution only.

[4] CLINICAL VENOM EFFECTS

Moderately powerful venom, principal effect being myolysis of skeletal muscle, with the potential for secondary renal failure and hyperkalaemia. True paralysis does not seem to occur with mulga snake bites, but the muscle damage may be severe enough to cause direct muscle weakness, which might mimic paralysis. The venom does not contain procoagulants, but rather direct anticoagulants. Defibrination coagulopathy is not seen, but there may be slight (occasionally marked) prolongation of clotting times, INR, APTT, due to the anticoagulants. Mulga snake bites are usually associated with significant local swelling and pain at the bite site. the swelling may take several hours to fully develop, but many days to fully subside.

[5] ANTIVENOM

Preferred antivenom is Seqirus Black Snake Antivenom. Usually one vial is sufficient.



[6] VENOM DETECTION

The expected pattern if Collett's snake venom is present is positive in well 3 + well 7 (positive control), but there may also be weak positive in well 1.

DEATH ADDERS

Genus *Acanthophis*

[1] EPIDEMIOLOGY

Death adders are now relatively rare in the wild in much of settled Australia, although there are a few areas where they are locally common. They do not appear to adapt well to human land use. As a result bites by death adders in the wild are extremely rare. In contrast they are common in captivity and bites to reptile keepers are moderately common. They have a potent venom and prior to antivenom, used to kill 50% of all people bitten. Death from death adder bite is now very rare.

[2] TAXONOMY

The death adders are squat snakes with a distinctive triangular head, narrow neck, and relatively short, dumpy body, compared to other dangerous snakes in Australia. Mid body scales are in 21-23 rows, with 110-160 ventral scales, an undivided anal scale, and 40-60 undivided subcaudal scales.

[3] DISTRIBUTION

Formerly far more widely distributed than now, they prefer habitats with leaf litter or other ground debris in which to hide, usually, but not exclusively, in sandy soils, including coastal dune country. The map shows approximate theoretical distribution only. The death adder is the only Australian dangerous venomous snake which is commonly active at night, and it is often reluctant to move away if humans approach; relying on being hidden in leaf litter, where it may be stepped on.

[4] VENOM EFFECTS

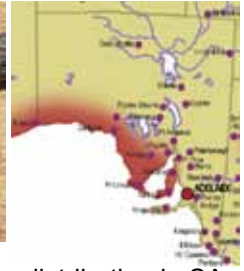Death adder venom is powerful, but limited in action. In man its effects are principally those of paralysis due to post synaptic neurotoxins, though presynaptic toxins are found in some specimens. This raises an interesting possibility in therapy, as post synaptic paralysis is often reversible with either antivenom or anticholinesterases. Death adders do not cause a defibrination type coagulopathy, rarely myolysis, and renal failure is not reported. Death adder bites are usually quite painful at the bite site, though swelling is usually only slight, and there is a tendency to local secondary infection.

[5] ANTIVENOM

The preferred antivenom is Seqirus Death Adder Antivenom, but at least in reptile keepers, where exposure to antivenom should be minimised, it is worth trying other therapies to reverse paralysis if present, reserving antivenom for those severe cases where such therapies fail. The suggested therapy is iv anticholinesterase (e.g. neostigmine + atropine) but beware of convulsions secondary to neostigmine therapy. A single vial is the usual initial antivenom dose.

[6] VENOM DETECTION

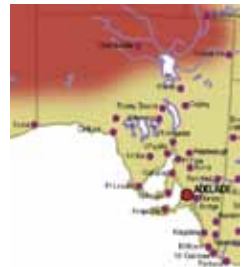The expected result is positive in well 4 + well 7 (positive control), but occasionally there may also be a weak positive in well 1.



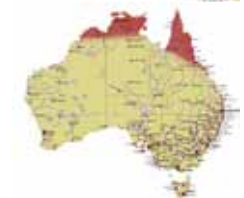Common death adder, *Acanthophis antarcticus*, and approximate distribution in SA.



Desert death adder, *Acanthophis pyrrhus*, and approximate distribution in SA.



Northern death adder, *Acanthophis praelongus*, not native to SA.



TAIPANS

Genus *Oxyuranus*

[1] EPIDEMIOLOGY

Taipans are popular amongst reptile keepers, and quite a few exist both in reptile parks, and in private collections, and bites do occur. The taipan is one of the world's most dangerous snakes, and prior to the development of an antivenom, nearly all cases were fatal. All taipan bites should be considered as potentially fatal, and require the most urgent attention. Because the problems they cause are complex, all cases should be managed in major hospitals, with full ICU, full laboratory facilities, and expert help from a Clinical Toxinologist/Toxicologist should always be sought.

[2] TAXONOMY

Taipans are large snakes, sometimes exceeding 2m in length, with mid body scales in 23 rows, 220-250 ventral scales, a divided anal scale, and 55-70 divided subcaudal scales. The inland taipan *Oxyuranus microlepidotus* often has a dark coloured head, and a speckled brown body. It is easily mistaken for a western brown snake. The common taipan *Oxyuranus scutellatus* is generally of brown colour, with pale belly and often a paler coloured angular head.

[3] DISTRIBUTION

The common taipan, *Oxyuranus scutellatus*, is not native to SA. The inland

taipan, *Oxyuranus microlepidotus*, is restricted to the far north west of the State, if present at all, in the black soil plains country. Neither species is likely to be common.

[4] CLINICAL VENOM EFFECTS

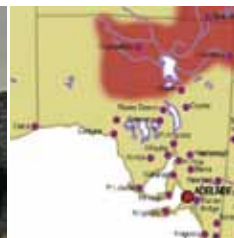
Taipans have very powerful venom in large amounts, and delivered by large fangs (up to 12 mm. for the common taipan). The venom has a wide spectrum of activity, including potent neurotoxins and procoagulants. Envenoming is usually accompanied by rapid onset of defibrination type coagulopathy, early or delayed onset of paralysis, and myolysis and renal failure may develop in some cases. The patient may be so severely envenomed that intubation is needed within 1-2 hours of the bite. Bites by taipans are the only Australian snakebites where it may sometimes be justified to commence antivenom therapy before systemic envenoming is established.

[5] ANTIVENOM

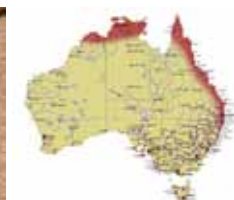Preferred antivenom is Seqirus Taipan Antivenom. However taipan antivenom is of similar volume and cost to polyvalent antivenom and therefore it is often more practical to stock and use polyvalent rather than taipan antivenom if the number of expected taipan bites is low (e.g. country hospital servicing a reptile park). In a metropolitan hospital where access to taipan antivenom directly from Seqirus after hours is possible, it is best to use the specific antivenom for therapy. Initial dose is 1 vial, but occasionally a higher initial dose may be required (some captive snakes).

[6] VENOM DETECTION

The expected result is positive in well 5 + well 7 (positive control), but for common taipan venom, there may also be weak positives in wells 1,3 and 4, while for the inland taipan there may be weak positives in wells 1 to 4, especially well 2.



Inland taipan *Oxyuranus microlepidotus*.



Common taipan *Oxyuranus scutellatus*.

EASTERN SMALL EYED SNAKE

Cryptophis nigrescens

[1] EPIDEMIOLOGY

In much of its range this snake is common, but few bites are recorded, though this does not imply actual bites are rare. There is one recorded fatality associated with delayed myolysis.

[2] TAXONOMY

This snake shares the genus with 5 other species, none of which are known to be of medical significance. It is a steel grey colour above, with a cream belly. The sides of the head may be yellowish to red brown. Midbody scales 15 rows, ventrals 145-190, anal undivided, 20-35 undivided subcaudals, length to 0.45 metres.

[3] DISTRIBUTION

Restricted to eastern Australia. Not native to SA. Nocturnal.

[4] CLINICAL VENOM EFFECTS

The single reported severe case occurred in 1968, the young man concerned dying more than a week after the bite with effects of severe myolysis. The venom does not appear neurotoxic, nor does it cause coagulopathy experimentally.

[5] ANTIVENOM

Antivenom is unlikely to be required for most bites by this snake, but should major envenoming occur, with myolysis, use Seqirus Tiger Snake Antivenom which has been shown effective in envenomed animals.

[6] VENOM DETECTION

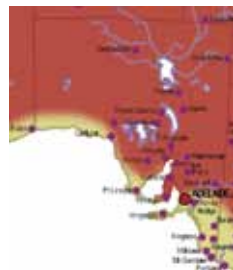There is currently no information on the reactivity of this venom with the SVDK, but because the principal toxin is similar to one of the major toxins in tiger snake venom, it is possible that it may cross react and bind to antibody in well 1, giving a positive result.

YELLOW FACED WHIP SNAKE

Demansia psammophis

[1] EPIDEMIOLOGY

This snake is included not because it is dangerous, but because it frequently causes bites. Envenoming by this snake may result in both local and general symptoms, but there is no evidence that it is potentially lethal, and therefore bites do not require antivenom therapy.



[2] TAXONOMY

The yellow faced whip snake grows to about 60 cms. long, and is thin of build, the average adult having a diameter approximating that of a standard biro. This is considerably smaller than most of the potentially lethal snakes. The colour is usually green to grey anteriorly, shading to a russet brown towards the tail, and with a distinctive pale ring around the eye. Mid body scales are in 15 rows, with 165-230 ventrals, a divided anal scale, and 60-105 undivided subcaudal scales.

[3] DISTRIBUTION

Common across much of Australia, including much of SA.

[4] CLINICAL VENOM EFFECTS

Few formal studies on the venom of this snake have been published, but it is not considered lethal to man. Bites usually cause local pain and swelling, sometimes with a mild systemic illness, but there is no evidence of paralysis, coagulopathy, myolysis, or renal failure.

[5] ANTIVENOM

Yellow faced whip snake bites do not need antivenom therapy, but may warrant admission overnight if there is significant local swelling, for elevation of the bite site.

[6] VENOM DETECTION

Venom of this snake may give positive results in the SVDK, either as “brown snake” (well 2), or as “tiger snake” (well 1), and this may cause confusion in interpretation of the SVDK results. Be aware of this in interpretation of SVDK results and in deciding on the need for antivenom therapy.

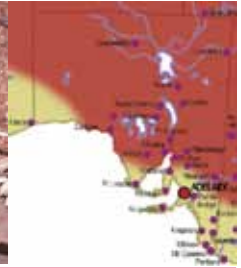OTHER ELAPID SNAKES

There are a variety of other species of elapid (cobra) type snakes in SA, in addition to the above mentioned dangerous species. Some, such as the curl snake, are of moderate size and may cause local pain and swelling, while others live most of their life burrowing, are small, and bites should only be trivial. A full discussion of all species is not appropriate in this document, however some brief information on species is listed.

None of these snakes are likely to cause medically significant bites requiring hospitalisation and antivenom treatment is not appropriate. However, it should be noted that very few of these snakes have had their venom investigated and for most there are few, if any records of bites. Should someone present following a bite by one of these snakes, it is most uncertain if the SVDK will produce a positive result. There is a possibility that venom might be detected, in an unpredictable manner, that might cause confusion with a dangerous species. The chance of such an event is not high, because bites by most of these snakes are unlikely. For many, their small size and cryptic lifestyle make encounters with humans rare and fang penetration would usually be difficult, even if a bite did occur, almost certainly in association with picking up and handling the snake.

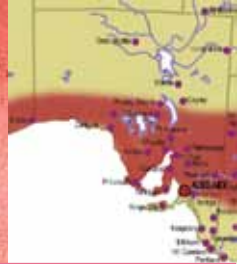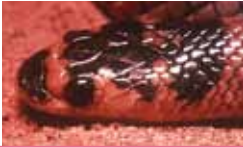curl snake, *Suta suta*

Curl snakes can cause mild local envenoming, with both swelling and pain, occasionally general symptoms such as headache and nausea, but do not cause life threatening envenoming. There is no evidence they can cause coagulopathy, paralysis or myolysis.



black headed snake, *Parasuta spectabilis*

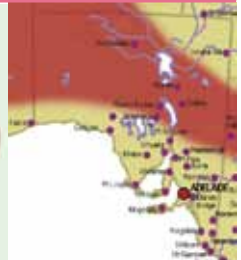There is no significant experience with bites by these snakes, but they are unlikely to cause more than local pain and swelling.



hooded snake, *Parasuta monachus*

There is no significant experience with bites by these snakes, but they are unlikely to cause more than local pain and swelling.

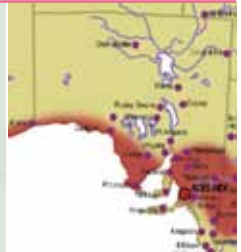Photo copyright © Dr. Mark Hutchinson, S.A. Museum



mallee back-headed snake, *Parasuta nigriceps*

There is no significant experience with bites by these snakes, but they are unlikely to cause more than local pain and swelling.

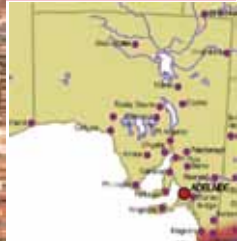Photo copyright © Dr. Mark Hutchinson, S.A. Museum

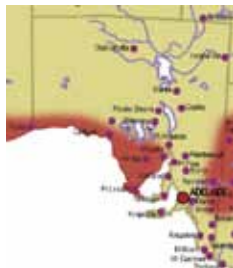

little whip snake, *Parasuta flagellum*

There is no significant experience with bites by these snakes, but they are unlikely to cause more than local pain and swelling.

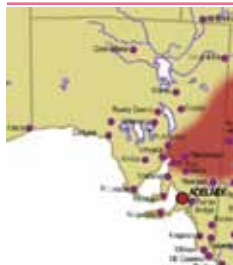Photo copyright © Dr. Mark Hutchinson, S.A. Museum





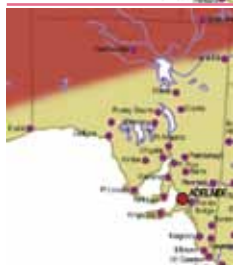
**bardick,
*Echiopsis curta***

Their small size makes effective envenoming of humans unlikely, other than perhaps mild local pain and swelling. There is no evidence they can cause coagulopathy, paralysis or myolysis. However, there is some evidence their venom may be detected in SVDK as death adder.



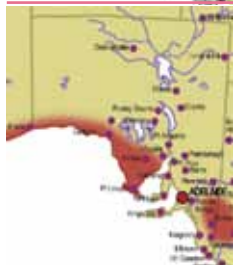**red naped snake,
*Furina diadema***

A small snake, unlikely to effectively bite humans or cause more than mild local pain or minimal swelling. However, another member of this genus has been reported to cause general symptoms, such as headache, vomiting and abdominal pain.



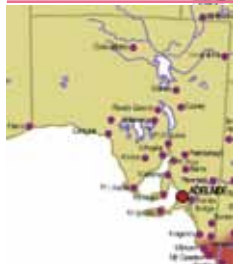**orange naped snake,
*Furina ornata***

A small snake, unlikely to effectively bite humans or cause more than mild local pain or minimal swelling. However, another member of this genus has been reported to cause general symptoms, such as headache, vomiting and abdominal pain.



**Master's snake,
*Drysdalia mastersii***

Their small size makes effective envenoming of humans unlikely, other than perhaps mild local pain and swelling. There is no evidence they can cause coagulopathy, paralysis or myolysis.



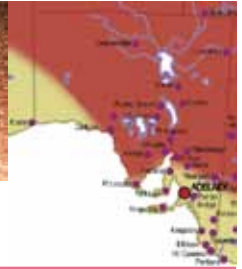**white lipped snake,
*Drysdalia coronoides***

Their small size makes effective envenoming of humans unlikely, other than perhaps mild local pain and swelling. There is no evidence they can cause coagulopathy, paralysis or myolysis.

Photo copyright © Dr. Mark Hutchinson, S.A. Museum

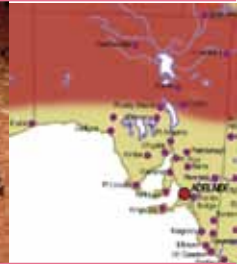
**desert banded snake,
*Simoselaps bertholdi***

One of several species of small, harmless burrowing elapid snakes, most commonly encountered at night or in pits or hollows in which they have become trapped. Harmless.



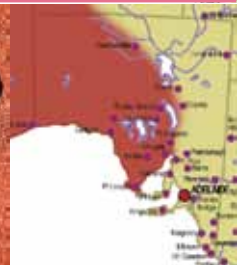**narrow banded burrowing snake,
*Brachyuropis fasciolatus***

Similar to the desert banded snake in habits. Harmless.



**half girdled snake,
*Brachyuropis semifasciatus***

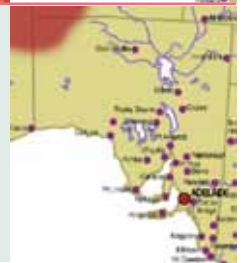
Similar to the desert banded snake in habits. Harmless.



**northern desert banded snake,
*Simoselaps anomalus***

Similar to the desert banded snake in habits. Harmless.

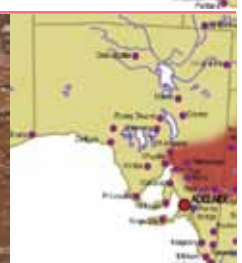Photo copyright © Dr. Mark Hutchinson, S.A. Museum



**coral snake,
*Brachyuropis australis***

Similar to the desert banded snake in habits. Harmless.

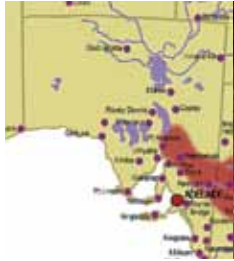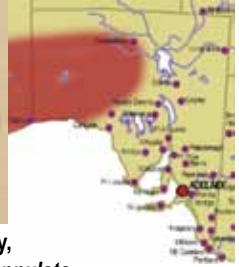Photo copyright © Dr. Mark Hutchinson, S.A. Museum



western black-naped snake, →
Neelaps bimaculatus

Similar to the desert banded snake in habits. Harmless.

Photo copyright © Dr. Mark Hutchinson, S.A. Museum



← bandy bandy,
Vermicella annulata

There is no evidence bandy bandys are likely to cause significant bites in humans. Indeed, the small head size may make it difficult for the snake to effectively bite in most cases.

PYTHONS

Several python species occur in S.A.. All are non-venomous, but have numerous long teeth and can cause significant local effects at a bite site. Because of the large number of teeth, the pattern of bite marks is likely to be quite distinct from a venomous snake bite. Secondary infection requiring antibiotic treatment may occur following python bites, and all patients should have their tetanus immunisation brought up to date. They are easily distinguished from venomous snakes by their high mid-body scale count.



woma python
Aspidites ramsayi



carpet python
Morelia spilotes



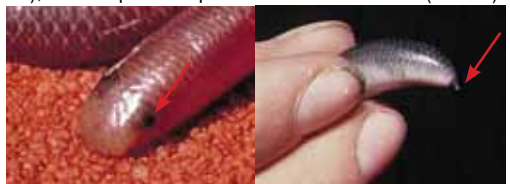head showing heat sensing pits
on lower lip & front of snout

BLIND SNAKES

There are numerous species of blind snakes; small burrowing snakes which are non-venomous and cannot bite humans. Their head shape has evolved for burrowing and is distinctive, as is the long, thin, cylindrical body. The tail ends in a sharp spine, which is not venomous and is used by the snake for leverage. All blind snakes are harmless to humans. They may be encountered in trenches or pits which they may fall into at night.



typical blind snake (above)
distinctive head of a blind snake with scales over the eyes (below), and the pointed spine on the end of the tail (bottom)



GENERAL INFORMATION ON RED BACK SPIDER BITE

The Australian red back spider, *Latrodectus hasselti*, is a member of the world-wide widow spider group, envenoming by these spiders being known as “latrodectism”. The venom contains excitatory neurotoxins which stimulate the nervous system rather than cause paralysis. An overview and management algorithm is available on pages 18,19.



Clinical Features

Possibly >50% of red back spider bites are minor, resulting in either minimal or no symptoms and do not require treatment with antivenom.

In a typical case of significant latrodectism, the patient will usually feel the bite as a minor sting only and may not see the spider. After a brief period of 10-50+ mins the bite area becomes painful. The pain increases to become severe and then spreads proximally, involving draining lymph nodes, which may become swollen and tender. Eventually envenoming may progress to generalised pain, localised or generalised sweating, hypertension and malaise. Many other symptoms may also occur, but are uncommon or less consistent. The generalised truncal pain may be chest pain, abdominal pain or neck or head pain, and may mimic the pain of myocardial infarction or acute abdomen. The progression from local to generalised pain may take from 1 to 24+ hours, though less than 6 hours for progression is seen in most cases.

There may little to see at the bite site, or an area of erythema, sometimes with a central blanched area, and local sweating may be evident. The latter is a classic feature of early latrodectism.

A history of a bite, followed by local, then regional or generalised pain plus increased localised or generalised sweating, sometimes with associated hypertension, is classic for latrodectism. In patients with delayed presentation or treatment, irrespective of where the bite site is located, the pain and increased sweating may gravitate to both legs, particularly below the knees, often with a burning sensation in the soles of the feet.

First Aid

There is no definitive first aid for latrodectism. Cold packs on the bite area sometimes help diminish pain. A snake bite type pressure bandage will make pain worse and is not recommended.

Treatment

All suspected or definite cases of red back spider bite with evidence of envenoming should be assessed in a hospital, but asymptomatic cases do not require hospital assessment and should be advised to seek medical care only if they become symptomatic. The role of antivenom is currently controversial and it should only be given only if there is a pattern of symptoms and signs consistent with significant envenoming that is unresponsive to a time-limited trial of analgesics, and

after careful discussion with the patient/guardian so that they provide at least verbal informed consent. Providing these criteria are met, full systemic envenoming is not a requirement to justify antivenom treatment for red back spider bite, unlike snake-bite.

As with all injuries causing skin penetration, ensure the patient has adequate tetanus immune status before discharge.

Criteria for significant envenoming are:

History of local pain becoming severe, spreading proximally, becoming regional or even truncal and severe in nature.

± Local or regional or generalised profuse sweating.

± Headache, malaise, nausea.

± Hypertension.

In a minority of cases pain is a minor feature, but profuse sweating is the major and distressing feature. As this is unlikely to be reduced by analgesics, AV may be a more appropriate first line treatment in such cases.

Antivenom

In cases where significant envenoming occurs, antivenom therapy has historically been the preferred treatment, though death is extremely unlikely in untreated cases of latrodectism. The value of Seqirus Red Back Spider Antivenom has been its apparent ability to dramatically improve the symptoms of latrodectism and allow a rapid return to activities of daily living.

However, the 2014 “RAVE 2” study (randomised double blind control trial of IV AV versus placebo) claimed that the AV was ineffective and instead treatment should be with analgesia alone, even though, in this study, analgesia arguably failed in 70% of cases.

There is therefore no current shared consensus on management of latrodectism in Australia. Prior to RAVE 2, there was >50 years experience in Australia with AV treatment of latrodectism, with generally good results, a finding mirrored in recent trials of AV treatment of latrodectism overseas. Similarly, analgesia was generally considered poorly effective for latrodectism, especially compared to AV.

There were, arguably, a number of problems with the RAVE 2 study that could be considered sufficient to question its validity in driving change of clinical practice, unless its findings are confirmed by an adequately powered and designed independent clinical trial of AV versus placebo, or AV versus analgesia.

Therefore, it is recommended in these Guidelines that AV remain an option in treating latrodectism and be considered in all cases where an initial time-limited trial of analgesia has failed to provide adequate relief of distressing symptoms or clear signs of significant envenoming. Except in cases with comparatively mild pain, standard oral analgesia is unlikely to be effective and therefore it is appropriate to trial potent oral or parenteral analgesics. If inadequate pain relief after 2 hours, or if other features of envenoming (profuse sweating, hypertension) are a problem, then it is appropriate to consider AV therapy.

This should be carefully discussed with the patient/guardian, so that they can give informed consent, at least verbally (and recorded in the case notes). ***They should be informed; (1)*** that without AV they are unlikely to die from latrodectism,

(2) that without AV the duration of distressing symptoms may be many hours to days, (3) that there is conflicting evidence about effectiveness of AV, (4) that there is a large body of experience successfully using the AV in Australia, spanning 50+ years, with no deaths from red back spider bite recorded since AV was introduced in 1956 (13 deaths prior to AV being available), (5) that most overseas evidence also supports the value of AV in treating latrodectism, (6) that experience in Australia indicates that AV will usually provide effective and sometimes dramatic control of symptoms, often within 2 hrs of administration, (7) that a small subset of patients, generally adults with delayed treatment, fail to respond to AV for reasons which remain unclear, (8) that like all antivenoms, red back spider AV can sometimes cause adverse reactions, including potentially life threatening anaphylaxis, but that these reactions can be treated successfully in a hospital setting and that there are no recorded deaths due to such reactions to this AV in Australia.

Seqirus Red Back Spider Antivenom is refined horse IgG F(ab')₂, averaging 1.5mL per vial. While the manufacturer states it can be given IM (intramuscularly) it is **preferable to administer it IV**, with all facilities ready to treat anaphylactic type reaction, including adrenaline 1:1,000 drawn up ready to use IM or SC. Anaphylaxis to this antivenom is rare. The **initial dose is 2 vials**. There is an increasing trend to using this AV IV. While initial research is encouraging that IV may be a better route, this has yet to be confirmed by definitive research. For IV administration dilute the antivenom in up to 100ml of normal saline and administer over about 20mins using a pump or similar. This method is to reduce the risk of allergic reaction. If the patient has been bitten by a red back spider, within 2 hours of administration of AV, often within 30mins, there should be some resolution of symptoms of envenoming. This may be a complete and permanent resolution, a partial resolution, or resolution with subsequent relapse. In the latter two situations, another 2 vials of antivenom should be given. Occasionally even a further dose of antivenom is required, but always seek expert advice before giving more AV. A case of suspected red back spider bite in which there is no discernible response to 4 vials of antivenom is most likely not a case of latrodectism. **If in any doubt ring for expert advice, WCH Clinical Toxicology Service, 8161 7000 & ask for the duty clinical toxicologist..**

Is it a red back spider bite or some other type of spider bite?

Often it is clear that the spider was, most likely, a red back spider, but this may not always be the case. A useful algorithm for deciding on the most likely type of spider has been developed (Isbister & Sibbritt 2004), with particular reference to “big black spiders” that might be a funnel web spider. This algorithm is shown on page 12. Like all such algorithms, it cannot cover all situations, but is a useful guide for clinicians. It has been designed to indicate the most likely spider group, based on circumstances of the bite (location, time of year, time of day) and early local clinical effects (specifically local diaphoresis or increased sweating). It then classifies the spider into one of three groups; (i) big black spiders, which includes funnel web spiders, (ii) red back spiders, (iii) all other spiders, which are, in general, unlikely to cause significant effects and are therefore of no great medical concern.

PROTOCOL FOR MANAGING FUNNEL WEB SPIDER BITE

BASIC INFORMATION

Funnel web spider bite is a medical emergency, potentially life threatening, and is NOT a simple matter of just giving antivenom. A management overview and algorithm is available on pages 20-21. **FOR EXPERT ADVICE**; call **WCH Clinical Toxinology Service, 8161 7000 & ask for the duty clinical toxicologist.**

A considerable number of funnel web spider bites do not result in significant illness, and do not require antivenom, but **ALL suspected or confirmed funnel web spider bites must be observed** for at least 4-6 hours. As with all injuries causing skin penetration, ensure the patient has adequate tetanus immune status before discharge.

As noted earlier in this document, funnel web spiders have a limited distribution in South Australia and bites are very rare, with none causing envenoming so far. The following information, based on guidelines for N.S.W., is included here for completeness, in the unlikely event that a significant funnel web spider bite occurred in S.A..

PROTOCOL

[1] [a] **Possible or definite funnel web spider bite:** GO TO Section [2].

OR

[b] **The patient presents unwell, diagnosis uncertain.** There is a history of possible exposure to funnel web spiders (i.e. in an area within the range of these spiders etc), and the patient has any of the following; tingling around lips, tongue fasciculation, excessive lachrymation, salivation, piloerection, hypertension, nausea, dyspnoea (pulmonary oedema), impaired conscious state: If after consideration it appears funnel web spider bite is a likely diagnosis, urgently consider antivenom therapy GO TO Section [3] for advice on management.

[2] [a] **The patient is unwell, possibly envenomed.** GO TO Section [3] (below).

OR

[b] **The patient is well, no apparent envenoming.** GO TO Section [6].

[3] **Management of the envenomed or possibly envenomed patient:**

[i] **Urgent Treatment:**

- Respiratory failure due to pulmonary oedema: artificial ventilation; mouth to mouth; bag/mask; bag/endotracheal tube as needed. Intubation and PEEP may assist in severe cases.
- Circulatory failure: if cardiac arrest, cardiopulmonary resuscitation.
- Insert an IV line (normal saline, run at maintenance, keep the patient fasted).
- If profound hypotension, IV volume restoration/electrolyte solution. A degree of hypertension is more commonly encountered.
- Seqirus Funnel Web Spider Antivenom is vital in treating systemic envenoming and is clearly an essential part of emergency management (see section [5] for details on administration).
- Apply pressure bandage/ immobilisation first aid, (remove when initial antivenom

therapy is completed).

- Blood samples:
 - complete blood picture
 - electrolytes, renal function, CK

[ii] History:

- was a spider seen to bite (?multiple bites) OR were the circumstances such that a bite might have occurred? Funnel web spiders often hang on after biting.
- when did the patient get bitten (elapsed time)?
- description of spider if possible (colour,size, shape, photo on a mobile phone)
- geographic place that the incident occurred
- timing and type of first aid and activity after the bite
- type and timing of symptoms; specifically ask about tingling around lips, tongue fasciculation, excessive lachrymation, salivation, piloerection, hypertension, nausea, dyspnoea (pulmonary oedema), impaired conscious state.
- relevant past history; specifically ask about allergy or past exposure to funnel web spider antivenom, atopic (allergy) history, renal, cardiac, or respiratory disease.

[iii] Examination:

- assess patient status looking for:
 - local piloerection at bite site (if unbandaged)
 - tongue fasciculation
 - increased lachrymation, salivation
 - piloerection
 - tachycardia, hypertension
 - pulmonary oedema

[iv] Determine if there is systemic envenoming.

If there is then ANTIVENOM therapy will almost certainly be needed.

Systemic envenoming is present if there is:

- tongue fasciculation
- increased lachrymation, salivation
- piloerection distant from bite site
- tachycardia, hypertension
- pulmonary oedema

If systemic envenoming is present, urgently consider ANTIVENOM therapy as this may be life saving; see Section [5] for guide-lines on use and techniques of administration.

[vi] Ongoing care:

Should include; constant nursing care, with specific instructions to look for evidence of developing systemic envenoming; monitor urine output; check and update tetanus immunisation status.

[vii] Once situation is stabilised it may be possible to remove all first aid, but this may be left on for several hours if there is severe systemic envenoming, as there is evidence that it may increase local destruction of venom (not seen with snake venoms).

[4] Venom Detection:

[i] There is no venom detection available for spider bites.

[5] Antivenom Therapy:

[i] Antivenom is the definitive treatment of envenoming, and is potentially life saving. Antivenom should only be used if there is systemic envenoming. Only a minority of patients bitten by funnel web spiders will require antivenom therapy.

[ii] See guide-lines in Section [3] [iv] for determining if systemic envenoming has occurred.

[iii] Antivenom administration:

- Antivenom for funnel web spider bite should **always be given IV**, with all facilities ready to hand to treat anaphylaxis in the rare event that it should occur (see section [5] [vi] for a suggested regime) (because of the nature of envenoming by funnel web spiders, with catecholamine storm, anaphylaxis is very unlikely).
- Have an IV line set up and running. Start infusion very slowly carefully observing patient for reaction (look for rash, hypotension, bronchospasm; in children warning signs also include nasal, palatal, or ocular pruritis, coughing, sneezing, profuse sweating, faecal or urinary urgency or incontinence, abdominal pain and a sense of impending doom), and increase rate aiming to give whole dose over about 15 to 20 minutes.

[iv] Antivenom dose:

- The minimum dose is two vials of the Seqirus Funnel Web Spider Antivenom.
- Children require the same dose as adults.
- Multiple bites or severe envenoming mandate higher doses; commence with at least 4 vials, and be prepared to give more. Eight vials is not unusual in a severe bite.
- If there is incomplete response to initial antivenom, give further doses until all significant symptoms and signs have resolved. Be aware that relapse may occur greater than 6 hours after initial response to therapy, requiring further doses of antivenom. If the only residual problem is pulmonary oedema this may well be an effect of envenoming, but consider the possibility of IV fluid overload as an alternative, especially in children who have received large amounts of IV fluid.

[v] Premedication prior to antivenom therapy:

- This is unnecessary for Seqirus Funnel Web Spider Antivenom. **Be fully prepared to treat anaphylaxis if it occurs** with adrenaline (see section [5] [vi] below for guidelines on use of adrenaline), volume load with SPPS, and such other measures as may be indicated.

[vi] Management of anaphylaxis:

(i) *Preparation prior to commencing antivenom.*

1. Dedicate one small bore (18-20 G in adults) IV line to antivenom administration, and one large bore IV line (16-14 G in adults) for emergency resuscitation.

2. Prepare 1L Normal Saline (20 ml/kg in children) ready to give under pressure.
3. Prepare adrenaline 1:1000 (1mg in 1 mL) drawn up to a dose of 0.01 mg/kg (max. 0.3 mg, i.e. max 0.3 mL) and label "adrenaline for i.m. injection only (dose in mg)".
4. Prepare an i.v. infusion of adrenaline 1mg in 100 mL (controlled by infusion pump or syringe driver) ready to attach by a side arm to the resuscitation line. Anti-reflux valves must be attached above the side arm on any other infusions using this i.v., to prevent adrenaline going back up into the other fluid bags. To prevent erroneous administration, do not attach the adrenaline infusion unless it is needed.
5. Record blood pressures on the other side to the fluid/adrenaline infusion, to avoid pronged cuff inflations and thus extravasation of infusion fluids.

(ii) Management of a reaction

Most reactions are related to the rate of antivenom infusion, and cause flushing, hypotension and bronchospasm. Some mild reactions resolve with temporary cessation of the antivenom infusion and recommencing it at a slower rate. It is important to be cautious when giving adrenaline to avoid blood pressure surges, which might lead to intracerebral haemorrhage.

Initial management of severe reactions (sudden hypotension, bronchospasm):

- Suspend the antivenom infusion
- Lie the patient flat (if not already), commence high flow/100% oxygen and support airway/ventilation as required
- Rapid infusion of 1L N Saline (20 mL/kg in children) over 2-3 minutes
- Adrenaline IM into the lateral thigh, 0.01 mg/kg to maximum of 0.3 mg (alternatively, those experienced with i.v. adrenaline infusions may proceed directly to this, as below)
- Liaise with toxicology service regarding ongoing management

For reactions that do not respond to initial management:

- If hypotensive, repeat Normal Saline bolus as above (up to 50 mL/kg may be required)
- Commence IV infusion of adrenaline (0.5-1 mL/kg/hour, of 1 mg in 100 mL) and titrate according to response; monitor BP every 3-5 minutes (using the arm opposite to the infusion); beware that as the reaction resolves adrenaline requirements will fall, the blood pressure will rise and the infusion rate will need to be reduced
- Consider nebulised salbutamol for bronchospasm, nebulised adrenaline for upper airway obstruction, and i.v. atropine for severe bradycardia
- Seek advice urgently from the local/regional ED Consultant &/or ICU Consultant

[6] The patient appears well, no apparent evidence of envenoming.

[i] Quickly ascertain:

History:

- was a spider seen to bite (?multiple bites) OR were the circumstances such that a bite might have occurred? Did the spider hang on to the bite site?
- when did the patient get bitten (elapsed time)?

- description of spider if possible (colour,size, shape, photo on mobile phone)
- geographic place that the incident occurred
- timing and type of first aid and activity after the bite
- type and timing of symptoms; specifically ask about tingling around lips, tongue fasciculation, excessive lachrymation, salivation, piloerection, hypertension, nausea, dyspnoea (pulmonary oedema), impaired conscious state.
- relevant past history; specifically ask about allergy or past exposure to antivenom, atopic (allergy) history, renal, cardiac, or respiratory disease.

Examination:

- assess patient status looking for:
- local piloerection at bite site (if unbandaged)
- tongue fasciculation
- increased lachrymation, salivation
- piloerection
- tachycardia, hypertension
- pulmonary oedema

Investigations: There are no investigations specific for funnel web spider envenoming.

- [ii] If after performing the above there is evidence of systemic envenoming then proceed as for Section [3] above.
- [iii] If after performing the above there is no clinical evidence of envenoming then observe the patient for a minimum of 4 hours after removal of first aid.
- [iv] As with all injuries causing skin penetration, ensure the patient has adequate tetanus immune status before discharge.

MOUSE SPIDERS

The mouse spiders of the genus *Missulena* are possibly of medical significance, as there is a single report of significant envenoming in a child bitten in SE Queensland. In this case, symptoms were similar to those seen in funnel web spider bite and there was some improvement following administration of funnel web spider antivenom. However, there are a considerable number of recorded bites from these spiders without any significant medical effects. This may just indicate a low rate of effective bites.



Venom research has demonstrated strong similarities in actions and toxicity between mouse spider and funnel web spider venoms. Similarly, research has indicated that mouse spider venom is neutralised by Seqirus Funnel Web Spider Antivenom. Therefore, in the unlikely event of major envenoming by a mouse spider, Seqirus Funnel Web Spider Antivenom is a recommended therapeutic option, with dosage as for funnel web spider envenoming.

MISCELLANEOUS SPIDERS AND OTHER ARTHROPODS

BLACK HOUSE SPIDER

This common black spider is often found in and around buildings, often in a funnel shaped web. It is more hairy and robust of body and legs than the red back spider. Bites often cause local pain, redness and sometimes a mild general malaise, but not the severe, spreading pain of latrodectism.

Treatment is symptomatic, with analgesics as necessary, updating tetanus immune status and antibiotics if there is clear evidence of secondary infection.



WHITE TAILED SPIDER

This common house hunting spider has gained a formidable reputation for causing skin damage, essentially unsubstantiated by case reports from mainland Australia. There are numerous cases of bites reported without any significant local injury or effects, with only mild local discomfort and a small red lump, settling after about 24 hours. In a major series of 130 confirmed cases, none developed either infection or skin damage.

Most cases of bites by this spider will probably not require any treatment. Should the bite area become red and painful over the first 24-48 hours, consider secondary infection as a cause and treat with antibiotics.



NECROTIC ARACHNIDISM

Most patients are either unaware of a bite or cannot adequately describe the spider, particularly since most cases occur at night or while gardening. Though the white-tailed spider is often blamed, there is now strong evidence that it does not cause skin injury and it should not be invoked as a cause of skin damage. There are other types of spider, particularly outside Australia, which can cause primary skin necrosis. Foremost amongst these is the recluse spider group (*Loxoscelis*), including the fiddleback spider, *Loxosceles rufescens*, now clearly implicated in some South Australian cases of "necrotic arachnidism".

If there is initial pain, then blistering and dusky colouration of the skin, developing over 2-7 days, with later darkening of the skin suggestive of developing skin necrosis, consider necrotic arachnidism, but only after all other causes have been excluded. Though the Americans have lived with *Loxoscelis* for many years, treatment remains controversial. Early surgical excision, steroids and antibiotics do not appear generally helpful, though secondary infection clearly requires treatment.

AN APPROACH TO THE INVESTIGATION AND DIAGNOSIS OF NECROTIC SKIN ULCERS PRESENTING AS SUSPECTED SPIDER BITES

(Adapted from: Isbister GK, Whyte IM. Suspected white-tail spider bite and necrotic ulcers. *Internal Medicine Journal* 2004; 34(1-2):38-44).

Establish whether or not there is a history of spider bite

Clear history of spider bite (better if spider is caught):

- Refer to information on definite spider bites

No history of spider bite:

- Investigation should focus on the clinical findings: ulcer or skin lesion
- Provisional diagnosis of a suspected spider bite is inappropriate

Clinical history and examination

Important considerations:

- Features suggestive of infection, malignant processes or vasculitis
- Underlying disease processes: diabetes, vascular disease
- Environmental exposure: soil, chemical, infective
- Prescription medications
- History of minor trauma

Specific historical information about the ulcer can assist in differentiating some conditions:

- Painful or painless
- Duration and time of progression
- Preceding lesion

Investigations

Skin biopsy:

- Microbiology: contact microbiology laboratory before collecting specimens so that appropriate material and transport conditions are used for fungi, *Mycobacterium* spp, and unusual bacteria
- Histopathology

Laboratory Investigations: may be important for underlying conditions (autoimmune conditions, vasculitis), including, but not be limited, to:

- Biochemistry (including liver and renal function tests)
- FBC and coagulation studies
- Autoimmune screening tests, cryoglobulins

Imaging:

- Chest radiography
- Colonoscopy
- Vascular function studies of lower limbs

Treatment

Local wound management

Treatment based on definite diagnosis or established pathology

Investigation and treatment of underlying conditions may be important, (eg, pyoderma gangrenosum or diabetes mellitus)

Follow-up and monitoring

The diagnosis may take weeks or months to be established, so patients must have ongoing follow-up.

Continuing management: co-ordinated with multiple specialities involved

if present. Hyperbaric oxygen therapy has been suggested and anecdotal cases suggest it may be beneficial if there is significant necrosis developing. It has not yet been proved by clinical trial and is clearly impractical as routine treatment of every case. Good wound care appears to be fundamental in treatment, along with elevation and rest of the affected area.

HUNTSMAN SPIDER

There are many species of huntsman spiders. Most are reluctant to bite, but can cause local pain and redness, usually of short duration only. Occasionally the pain is more severe and the patient may feel generally unwell for about 24 hours.

Most cases of bites by this spider will probably not require any treatment. Should the bite area become red and painful over the first 24-48 hours, consider secondary infection as a cause and treat with antibiotics.



STEATODA SPIDER

This common relative of the red back spider looks similar to the red back, except it never has the red markings, being a uniform black. Its bites can cause local pain and redness, but usually not the spreading severe pain of latrodectism.

Most cases of bites by this spider will probably not require any treatment. Should the bite area become red and painful over the first 24-48 hours, consider secondary infection as a cause and treat with antibiotics. For rare cases showing features of latrodectism, Seqirus Red Back Spider Antivenom should be considered.



ORB WEAVING SPIDERS

There are a vast number of species, sizes and shapes of these common spiders, all characterised by the use of orb shaped webs to catch their prey. Most species are too small to bite humans effectively, but a few of the larger species may cause mild to moderate local pain and redness of usually short duration, without significant systemic effects.

Most cases of bites by this spider will probably not require any treatment. Should the bite area become red and painful over the first 24-48 hours, consider secondary infection as a cause and treat with antibiotics.



WOLF SPIDERS

These common ground hunters are well represented in arid areas, often living in burrows in the ground, sometimes with a palisade at the entrance, or even a trapdoor. Their big eyes give eyeshine at night when spotlighting. Few bites are recorded in Australia and they are unlikely to cause more than mild local pain and redness of short duration. Given their commonness, they are reluctant to bite.

Most cases of bites by this spider will probably not require any treatment. Should the bite area become red and painful over the first 24-48 hours, consider secondary infection as a cause and treat with antibiotics.



MITTURGID SPIDERS

These often large spiders are superficially similar to wolf spiders, but with less prominent eyes. Little is known about their bites, but local pain and redness might be expected.

Most cases of bites by this spider will probably not require any treatment. Should the bite area become red and painful over the first 24-48 hours, consider secondary infection as a cause and treat with antibiotics.



SCORPIONS

Many scorpions are found in Australia, but none are dangerous. Most live either under rocks or debris or in deep twisting burrows they dig in the sand. All are active at night. Their sting, in the tail, usually causes intense local pain lasting 15-45 mins, occasionally longer, but only rarely are there any systemic symptoms.

Most cases of scorpion stings will probably not require any treatment. If pain is very severe and prolonged then analgesics may be required. Should the sting area become red and painful over the first 24-48 hours, consider secondary infection as a cause and treat with antibiotics.



CENTIPEDES

The larger centipedes can bite humans, using the fangs at the front of the head, not the harmless tail appendages. The venom can cause intense local pain, similar to scorpion sting, but also some mild local skin damage, and secondary infection is always possible and not rare.

Most cases of centipede bites will probably not require any treatment. If pain is very severe and prolonged then analgesics may be required. Should the bite area become red and painful over the first 24-48 hours, consider secondary infection as a cause and treat with antibiotics.



INSECTS

Many insects can either sting or bite humans, but few cause more than minor local irritation, except in hypersensitive individuals. Some Hymenoptera, such as bees, wasps and primitive ants such as inch or bulldog ants, have a sting in their abdomen/tail attached to a venom gland. Stings can be quite painful and may result in allergic reactions, up to and including anaphylaxis. Secondary infection, though uncommon, may occur. Honey bees leave their sting in the wound, but wasps and ants do not, so may sting more than once.

Application of a local cold pack may help reduce pain and swelling. If there is a history of increasingly severe local reactions to stings, or any form of systemic reaction, the patient should be referred to an immunologist or allergist for consideration of desensitisation therapy and instructed on what to do if there is an anaphylactic reaction. In selected cases it may be justified to give the patient an adrenaline inhaler or injection set, together with comprehensive instructions on use.



RECOMMENDED FURTHER READING

The following books are useful sources of further information and are not listed in order of importance. There are many papers published on aspects on envenoming, relevant to Australia, which may be found in a variety of journals or via Index Medicus.

- COGGER, H.G. (2014) *Reptiles and Amphibians of Australia*, 7th edition. Melbourne:CSIRO Publishing.
- COVACEVICH, J., DAVIE, P., PEARN, J. Eds. (1987) *Toxic Plants and Animals: A Guide for Australia*. Brisbane:Queensland Museum.
- EHMANN, H. (1992) *Encyclopedia of Australian Animals: Reptiles*. Sydney:Angus & Robertson.
- ISBISTER, G.K., WHITE, J. (2004) Clinical consequences of spider bites: recent advances in our understanding. *Toxicon*, 43(5):477-492.
- ISBISTER, G.K., PAGE, C.B., BUCKLEY, N.A., FATOVICH, D.M., PASCU, O., MACDONALD, S.P.J., CALVER, L.A., BROWN, S.G.A. (2014) Randomized Controlled Trial of Intravenous Antivenom Versus Placebo for Latrodectism: The Second Redback Antivenom Evaluation (RAVE-II) Study. *AnnEmergMed*, 64(6):620-8.
- JACOB, J. & WHITE, J. (2017) Widow and related Latrodectus spiders. In eds. Brent, J. et al, *Critical Care Toxicology*, 2nd edition. Switzerland:Springer. pps 2595-2606.
- MEIER, J., WHITE, J. Eds. (1995) *Handbook of Clinical Toxicology of Animal Venoms and Poisons*. Boca Raton:CRC Press.
- MIRTSCHIN, P., RASMUSSEN, A.R., & WEINSTEIN, S.A. (2017) *Australia's Dangerous Snakes; Identification, Biology and Envenoming*. Melbourne:CSIRO Publishing.
- PEARN, J., COVACEVICH, J. (1988) *Venoms and Victims*. Brisbane:Queensland Museum & Amphion Press.
- SHINE, R. (1991) *Australian Snakes: A Natural History*. Sydney:Reed Books.
- SKINNER, A. (2009) A multivariate morphometric analysis and systematic review of *Pseudonaja* (Serpentes, Elapidae, Hydrophiinae). *ZooJLinSoc.*, 155:171-197
- SUTHERLAND, S.K., TIBBALLS J. (2001) *Australian Animal Toxins*. Melbourne:Oxford University Press. 2nd edition.
- WHITE, J. (1981) Ophidian envenomation: a South Australian perspective. *Rec-AdelChildrensHosp*. 2(3):311-421.
- WHITE, J. (2004) Elapid snakes. In ed. Dart, R. *Medical Toxicology*, Lippincott, Williams & Wilkins, pps 1566-1578.
- WHITE, J. (2005) Snake venoms and coagulopathy. *Toxicon*, 45:951-967.
- WHITE, J. (2013) *A Clinician's Guide to Australian Venomous Bites and Stings*. Melbourne:CSL Ltd.
- WHITE, J. (2017) Overview of snake envenoming. In eds. Brent, J. et al, *Critical Care Toxicology*, 2nd edition. Switzerland:Springer. pps 2279-2318.
- WHITE, J. (2017) Australian and Pacific Snakes. In eds. Brent, J. et al, *Critical Care Toxicology*, 2nd edition. Switzerland:Springer. pps 2405-2440.
- WHITE, J. (2017) Overview of spider envenoming. In eds. Brent, J. et al, *Critical Care Toxicology*, 2nd edition. Switzerland:Springer. pps 2551-2564.
- WHITE, J. (2017) Australian funnel web spiders. In eds. Brent, J. et al, *Critical Care Toxicology*, 2nd edition. Switzerland:Springer. pps 2565-2576.

HOSPITAL SPECIFIC INFORMATION

The table on the following pages lists each SA hospital, with occurrence of major venomous snakes in the hinterland for each hospital (shown as “+” if present or possibly present; “-” if absent or unlikely to be present). Such a listing is approximate, because detailed information on precise point by point distribution for each species is not available. It is meant as a guide, not an absolute statement of what may be found in the area.

On the opposite page the table lists recommended antivenom stocks for each listed hospital. These recommendations are based on a review of risks, facilities, past usage and other practical considerations. Some hospitals will only hold stocks to initiate treatment of one case of major envenoming by a given type of snake or a red back spider. It is important is that stocks are sufficient to at least start treatment, while further stocks and/or retrieval are being sought. For those hospitals with stock levels just sufficient for an initial dose for brown snake or tiger snake type envenoming, it is expected that available stocks will only be used where clearly clinically indicated, while awaiting supplemental stocks from another hospital and/or a retrieval.

For small country hospitals with limited resources and no access to on-site laboratory testing, the decision to stock any antivenom must be based on distance to a more major hospital versus risk and local resources. Each hospital has been evaluated separately as each has it's own unique characteristics. Thus one hospital with very limited resources may be recommended to stock antivenom, while a similarly resourced hospital elsewhere may not be recommended to stock any antivenom at all. Such differences will reflect degree of isolation and risk.

It is critically important in assessing a case of suspected snakebite to be able to determine degree of systemic envenoming in all four major risk areas; neurotoxic flaccid paralysis; coagulopathy; myolysis; renal damage. While the first, paralysis, is principally assessed clinically, the other three rely on laboratory testing. Because of this, it is always preferable to manage snakebite cases in hospitals with full laboratory facilities. This will exclude most country hospitals. However, the use of a clean glass test tube to conduct a 20 minute whole blood clotting test (20WBCT) will allow even small country hospitals to commence meaningful initial assessment. This may allow an early decision to administer antivenom, after discussion with a consultant clinical toxinologist from the SA Clinical Toxinology Service based at the Women's & Children's Hospital (WCH 8161 7000 & ask for the duty clinical toxinologist).

HOSPITAL SPECIFIC INFORMATION

Major dangerous snake groups found in approximate hospital hinterland.

<i>Hospital</i>	<i>Brown snakes</i>	<i>Tiger snakes</i>	<i>Copper-heads</i>	<i>Mulga snake</i>	<i>Red bellied black snake</i>	<i>Inland taipan</i>	<i>Death adders</i>	<i>Yellow faced whip snake</i>
Angaston Hospital	+	-	-	-	+	-	-	+
Balaklava Hospital	+	-	-	-	+	-	-	+
Barmera Hospital	+	+	-	+	-	-	-	+
Berri Hospital	+	+	-	+	-	-	-	+
Booleroo Centre Hospital	+	-	-	+	-	-	-	+
Bordertown Hospital	+	+	-	-	-	-	-	-
Burra Hospital	+	-	-	+	-	-	-	+
Ceduna Health Service	+	+	-	+	-	-	+	+
Central Yorke Peninsula Hospital, Maitland	+	-	-	-	-	-	-	+
Clare Hospital	+	-	-	-	-	-	-	+
Cleve Hospital	+	-	-	+	-	-	+	+
Coober Pedy Hospital	+	-	-	+	-	+	+	+
Cowell Hospital	+	-	-	+	-	-	+	+
Crystal Brook Hospital	+	-	-	-	-	-	-	+
Cummins Hospital	+	-	-	+	-	-	+	+
Elliston Hospital	+	-	-	+	-	-	+	+
Eudunda Hospital	+	-	-	-	+	-	-	+
Flinders Medical Centre	+	+	+	-	+	-	-	-
Gawler Health Service	+	-	-	-	-	-	-	-
Gumeracha Hospital	+	-	+	-	+	-	-	+
Hawker Hospital	+	-	-	+	-	-	-	+
Jamestown Hospital	+	-	-	-	-	-	-	+
Kangaroo Island Hospital	-	+	+	-	-	-	-	-
Kapunda Hospital	+	-	-	-	+	-	-	+
Karoonda Hospital	+	-	-	-	-	-	-	+
Kimba Hospital	+	-	-	+	-	-	+	+
Kingston Hospital	+	+	-	-	-	-	-	-
Lameroo Hospital	+	-	-	-	-	-	-	+

HOSPITAL SPECIFIC INFORMATION

Recommended antivenom stocks for each hospital.

<i>Hospital</i>	<i>Brown snake AV</i>	<i>Tiger snake AV</i>	<i>Black snake AV</i>	<i>Death adder AV</i>	<i>Taipan AV</i>	<i>Poly-valent AV</i>	<i>Red back spider AV</i>	<i>Funnel web spider AV</i>	<i>SVDC</i>
Angaston Hospital	0	0	0	0	0	0	0	0	0
Balaklava Hospital	2	0	0	0	0	0	2	0	1
Barmera Hospital	0	0	0	0	0	0	0	0	0
Berri Hospital	4	4	1	0	0	1	2	0	2
Boooleroo Centre Hospital	2	0	0	0	0	0	2	0	1
Bordertown Hospital	2	1	0	0	0	0	2	0	1
Burra Hospital	0	0	0	0	0	0	2	0	0
Ceduna Health Service	2	2	0	0	0	1	2	0	1
Central Yorke Peninsula Hospital, Maitland	0	0	0	0	0	0	0	0	0
Clare Hospital	2	0	0	0	0	0	2	0	1
Cleve Hospital	2	0	1	0	0	0	2	0	1
Cooper Pedy Hospital	2	0	0	0	0	1	2	0	1
Cowell Hospital	0	0	0	0	0	0	0	0	0
Crystal Brook Hospital	0	0	0	0	0	0	0	0	0
Cummins Hospital	2	0	0	0	0	1	0	0	1
Elliston Hospital	2	0	0	0	0	1	2	0	1
Eudunda Hospital	0	0	0	0	0	0	0	0	0
Flinders Medical Centre	4	2	1	1	0	2	4	0	2
Gawler Health Service	0	0	0	0	0	0	2	0	0
Gumeracha Hospital	0	0	0	0	0	0	0	0	0
Hawker Hospital	2	0	1	0	0	0	2	0	1
Jamestown Hospital	2	0	0	0	0	0	2	0	1
Kangaroo Island Hospital	0	2	0	0	0	0	2	0	0
Kapunda Hospital	0	0	0	0	0	0	0	0	0
Karoonda Hospital	0	0	0	0	0	0	0	0	0
Kimba Hospital	0	0	0	0	0	0	0	0	0
Kingston Hospital	2	2	0	0	0	0	2	0	1
Lameroo Hospital	2	0	0	0	0	0	2	0	1

Major dangerous snake groups found in approximate hospital hinterland.

<i>Hospital</i>	<i>Brown snakes</i>	<i>Tiger snakes</i>	<i>Copper-heads</i>	<i>Mulga snake</i>	<i>Red bellied black snake</i>	<i>Inland taipan</i>	<i>Death adders</i>	<i>Yellow faced whip snake</i>
Leigh Creek Hospital	+	-	-	+	-	-	-	+
Loxton Hospital	+	+	-	-	-	-	-	+
Lyell McEwin Hospital	+	-	-	-	+	-	-	-
Mannum Hospital	+	+	-	-	+	-	-	+
Meningie Hospital	+	+	-	-	+	-	-	-
Mid-West Health, Wudinna	+	-	-	+	-	-	+	+
Millicent Hospital	+	+	+	-	-	-	-	-
Modbury Hospital	+	-	+	-	+	-	-	+
Mount Barker Hospital	+	+	+	-	+	-	-	+
Mount Gambier Hospital	+	+	+	-	-	-	-	-
Mount Pleasant Hospital	+	+	-	-	+	-	-	+
Murray Bridge Hospital	+	+	-	-	+	-	-	+
Naracoorte Health Service	+	+	+	-	-	-	-	-
Noarlunga Health Service	+	+	-	-	+	-	-	-
Orroroo Health Service	+	-	-	+	-	-	-	+
Penola Hospital	+	+	+	-	-	-	-	-
Peterborough Hospital	+	-	-	+	-	-	-	+
Pinnaroo Hospital	+	-	-	-	-	-	-	+
Port Augusta Hospital	+	+	-	+	-	-	+	+
Port Broughton Hospital	+	-	-	-	-	-	+	+
Port Lincoln Hospital	+	+	-	+	-	-	+	+
Port Pirie Hospital	+	+	-	+	-	-	+	+
Quorn Health Service	+	+	-	+	-	-	-	+
Renmark Hospital	+	+	-	+	-	-	-	+
Repatriation Hospital	+	-	-	-	-	-	-	-
Riverton Hospital	+	-	-	-	+	-	-	+
Rocky River Health Service	+	-	-	-	-	-	-	+
Roxby Downs Health Service	+	-	-	+	-	+	+	+

Recommended antivenom stocks for each hospital.

<i>Hospital</i>	<i>Brown snake AV</i>	<i>Tiger snake AV</i>	<i>Black snake AV</i>	<i>Death adder AV</i>	<i>Taipan AV</i>	<i>Poly-valent AV</i>	<i>Red back spider AV</i>	<i>Funnel web spider AV</i>	<i>SVDK</i>
Leigh Creek Hospital	2	0	1	0	0	0	2	0	1
Loxton Hospital	2	2	0	0	0	0	2	0	1
Lyell McEwin Hospital	4	2	0	0	0	1	4	0	2
Mannum Hospital	2	2	0	0	0	0	0	0	1
Meningie Hospital	2	2	0	0	0	0	0	0	1
Mid-West Health, Wudinna	2	0	0	0	0	1	2	0	1
Millicent Hospital	2	2	0	0	0	0	2	0	1
Modbury Hospital	2	0	0	0	0	1	2	0	1
Mount Barker Hospital	2	2	0	0	0	0	2	0	1
Mount Gambier Hospital	4	4	0	0	0	0	2	0	2
Mount Pleasant Hospital	2	0	0	0	0	0	2	0	1
Murray Bridge Hospital	2	2	0	0	0	0	2	0	1
Naracoorte Health Service	2	2	0	0	0	0	2	0	1
Noarlunga Health Service	2	0	0	0	0	0	2	0	1
Orroroo Health Service	2	0	0	0	0	1	2	0	1
Penola Hospital	0	0	0	0	0	0	2	0	0
Peterborough Hospital	0	0	0	0	0	0	0	0	0
Pinnaroo Hospital	2	0	0	0	0	0	2	0	1
Port Augusta Hospital	4	2	1	0	0	2	4	0	2
Port Broughton Hospital	0	0	0	0	0	0	2	0	0
Port Lincoln Hospital	4	2	0	0	0	1	4	0	2
Port Pirie Hospital	2	2	0	0	0	1	4	0	1
Quorn Health Service	0	0	0	0	0	0	0	0	0
Renmark Hospital	2	2	0	0	0	1	2	0	1
Repatriation Hospital	0	0	0	0	0	0	0	0	0
Riverton Hospital	0	0	0	0	0	0	0	0	0
Rocky River Health Service	0	0	0	0	0	0	0	0	0
Roxby Downs Health Service	2	0	0	0	0	1	2	0	1

Major dangerous snake groups found in approximate hospital hinterland.

<i>Hospital</i>	<i>Brown snakes</i>	<i>Tiger snakes</i>	<i>Copper-heads</i>	<i>Mulga snake</i>	<i>Red bellied black snake</i>	<i>Inland taipan</i>	<i>Death adders</i>	<i>Yellow faced whip snake</i>
Royal Adelaide Hospital	+	+	+	-	+	-	-	-
SA Ambulance Service								
Snowtown Hospital	+	-	-	-	-	-	-	+
South Coast District Hospital, Victor Harbor	+	+	-	-	+	-	-	-
Strathalbyn Health Service	+	+	+	-	+	-	-	+
Streaky Bay Hospital	+	+	-	+	-	-	+	+
Tailem Bend Hospital	+	+	-	-	+	-	-	+
Tanunda Hospital	+	-	-	-	+	-	-	+
The Queen Elizabeth Hospital	+	-	-	-	-	-	-	-
Tumby Bay Hospital	+	+	-	+	-	-	+	+
Waikerie Health Service	+	+	-	+	+	-	+	+
Walleroo Hospital	+	-	-	-	-	-	+	+
Whyalla Hospital	+	-	-	+	-	-	+	+
Women's & Children's Hospital	+	+	+	-	+	-	-	-
Woomera Hospital	+	-	-	+	-	-	+	+
Yorke town Hospital	+	+	-	-	-	-	-	+

Recommended antivenom stocks for each hospital.

<i>Hospital</i>	<i>Brown snake AV</i>	<i>Tiger snake AV</i>	<i>Black snake AV</i>	<i>Death adder AV</i>	<i>Taipan AV</i>	<i>Poly-valent AV</i>	<i>Red back spider AV</i>	<i>Funnel web spider AV</i>	<i>SVDK</i>
Royal Adelaide Hospital	6	4	1	2	2	2	6	4	3
SA Ambulance Service	0	0	0	0	0	0	0	0	0
Snowtown Hospital	0	0	0	0	0	0	0	0	0
South Coast District Hospital, Victor Harbor	2	2	0	0	0	0	2	0	1
Strathalbyn Health Service	0	0	0	0	0	0	0	0	0
Streaky Bay Hospital	2	0	0	0	0	1	2	0	1
Tallem Bend Hospital	0	0	0	0	0	0	0	0	0
Tanunda Hospital	2	0	0	0	0	1	2	0	1
The Queen Elizabeth Hospital	2	0	0	0	0	0	2	0	1
Tumby Bay Hospital	2	2	0	0	0	1	2	0	1
Waikerie Health Service	2	2	0	0	0	0	2	0	1
Wallaroo Hospital	2	0	0	0	0	0	2	0	1
Whyalla Hospital	4	2	1	0	0	1	4	0	2
Women's & Children's Hospital	4	2	1	0	0	1	4	1	2
Woomera Hospital	2	0	1	0	0	0	2	0	1
Yorketown Hospital	2	2	0	0	0	0	2	0	1